

Case Report

A rare cause of hemoperitoneum – Gynecological emergency

S. Shanmuga Jayanthan¹, G. Rupesh¹, T. Devipriya¹, K. Nadasadharam¹

¹Department of Radiology, Meenakshi Hospital, Thanjavur, Tamil Nadu, India.

*Corresponding author:

S. Shanmuga Jayanthan,
Department of Radiology,
Meenakshi Hospital, Thanjavur,
Tamil Nadu, India.

jettan.32@gmail.com

Received: 21 March 2023
Accepted: 28 March 2023
Epub Ahead of Print: 12 April 2023
Published: 13 July 2024

DOI
10.25259/CRCR_42_2023

Quick Response Code:



ABSTRACT

Uterine fibroids are common benign smooth muscle tumors, at times may present with acute life-threatening complications. Spontaneous hemorrhage from a uterine fibroid is extremely rare but do occur. Herein, we report a case of a 36-year-old woman with acute onset of abdominal pain and diagnosed with hemoperitoneum for which emergency laparotomy was performed.

Keywords: Hemoperitoneum, Uterine fibroid, Subserosal fibroid, Hysterectomy

INTRODUCTION

Uterine fibroid (leiomyoma) is the most common benign tumor of uterine myometrium which is often asymptomatic but complications do occur. Sub-serosal leiomyoma is a type of uterine fibroid which may be attached directly to the uterus or by a thin stalk, which is also known as a pedunculated fibroid. Intraperitoneal bleeding (hemoperitoneum) is an extremely rare but serious complication of uterine fibroid, with only few cases reported in the literature. We report a case of hemoperitoneum due to a subserosal uterine fibroid, highlighting the importance of the role of imaging in the early diagnosis of this rare complication.

CASE REPORT

A 36-year-old woman presented to our Emergency department with chief complaints of acute abdomen pain and vomiting for 1 day. No history of trauma. The patient was pale with BP 60/40 and heart rate 125/min with a feeble pulse. On examination, the abdomen was distended and tense with tenderness in the lower abdomen. Menstrual history was regular, with moderate flow associated with pain. Obstetric history: G2P2 and both were normal vaginal delivery. Her urine pregnancy test was negative. The patient presented with hypovolemic shock. Bedside ultrasound (USG) abdomen was done which revealed the presence of free fluid with internal echoes and septations in the pelvis. The patient was stabilized and computed tomography (CT) abdomen and pelvis was taken for further evaluation.

Non-contrast CT axial and sagittal section at the level of pelvis revealed a solitary, well-defined, and pedunculated sub-serosal isodense mass lesion, arising from the anterior aspect of uterine fundus, measuring (6.5 × 7.7 × 7.9 cm) (AP × ML × CC) [Figure 1] with a hyperdense pelvic collection-suggestive of bleed/hemoperitoneum [Figure 1]. Contrast enhanced CT axial and sagittal section at the level of pelvis showed moderate enhancement of the lesion with prominent dilated vessels within it [Figure 1]. No active arterial contrast extravasation was noted on arterial phase CT.

This is an open-access article distributed under the terms of the Creative Commons Attribution-Non Commercial-Share Alike 4.0 License, which allows others to remix, transform, and build upon the work non-commercially, as long as the author is credited and the new creations are licensed under the identical terms.

©2024 Published by Scientific Scholar on behalf of Case Reports in Clinical Radiology

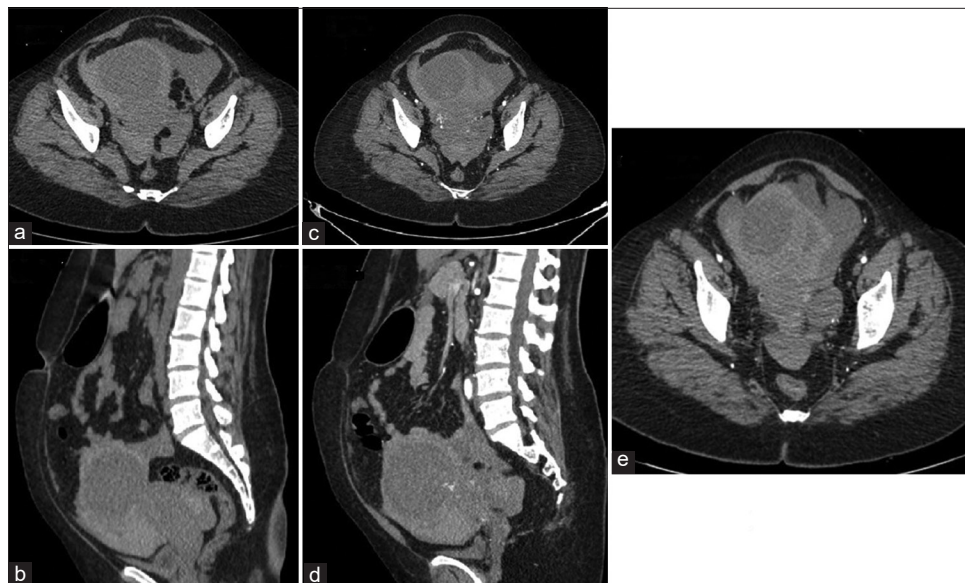


Figure 1: Non-contrast computed tomography (CT) (a) axial and (b) sagittal section at the level of pelvis revealed well defined, pedunculated sub-serosal isodense mass lesion noted, arising from the anterior aspect of uterine fundus. Contrast-enhanced CT arterial phase, (c) axial and (d) sagittal section at the level of pelvis shows moderate enhancement with prominent dilated vessels noted within the lesion. No active arterial contrast extravasation was noted. Contrast-enhanced CT arterial phase, (e) axial section shows moderate pelvic collection with internal hyperdense contents noted suggestive of hemorrhage.

Magnetic resonance imaging (MRI) axial and sagittal section at the level of pelvis showed a well-defined pedunculated sub-serosal T1 iso-hypo [Figure 2]/T2 hyper-intense mass lesion [Figure 2], arising from the anterior aspect of uterine fundus, of size – (6.5 × 7.7 × 7.9 cm) (AP × ML × CC), with prominent intralesional flow voids - suggestive of feeding vessels [Figure 2]. Moderate pelvic collection with T1 hyperintense content (hemorrhage) and blood fluid levels was noted. By International Federation of Gynecology and Obstetrics classification of uterine fibroid, it was classified as Type 7 complicated with hemoperitoneum.

The patient was shifted for an emergency hysterectomy and intraoperatively, it was found that there was an ooze from the surface of the fibroid [Figure 3]. Histopathological examination was confirmed as cellular fibroid.

DISCUSSION

Uterine fibroids are reported to occur in ~25% of females in the reproductive age group.^[1] It is also the most common benign smooth muscle tumor of uterus. Sub-serosal fibroid is a type of uterine fibroid which may be attached directly to the uterus or by a thin stalk, which is also known as a pedunculated fibroid.^[2] Mostly fibroids are asymptomatic but can be symptomatic at times. These include heavy menstrual bleeding, low back pain, frequent urination, and pain during sex. Acute complications are relatively rare which includes

torsion of the pedunculated fibroid, urinary retention, thromboembolism, and bleeding from degenerated fibroid.

Acute hemoperitoneum, as a complication of uterine fibroid, is extremely uncommon. In most cases, it is caused by the rupture of a subserosal vessel overlying a uterine fibroid. The reason for this phenomenon is yet unclear. Several predisposing factors include trauma, exercise, defecation, and menstruation.^[3] The size of the fibroid is considered to be an independent risk factor for the surface vein rupture, leiomyomas >10 cm are at higher risk of bleeding.^[4] Most patients present with severe lower abdominal pain, vomiting and sometimes with hypovolemic shock. Awareness and a high level of suspicion is needed to diagnose this complication early as they are life threatening.^[5]

Hemoperitoneum, resulting from rupture of sub-serosal vessels of fibroid, requires an immediate active intervention. The other common obstetric and gynecological and non-traumatic causes of haemoperitoneum include ruptured ectopic pregnancy, ruptured ovarian cyst and endometriosis.^[4] Malignant tumors like leiomyosarcoma can also cause massive hemoperitoneum rarely. Imaging plays a key role in the diagnosis of the above pathologies.

Imaging modalities such as USG and CT are commonly used for pre-operative diagnosis.^[6] Ruptured ectopic pregnancy is often diagnosed with USG substantiated by clinical history and Urine pregnancy test (UPT). Thickening of endometrium with absent intrauterine gestation sac and complex adnexal mass are often the imaging findings in the diagnosis of

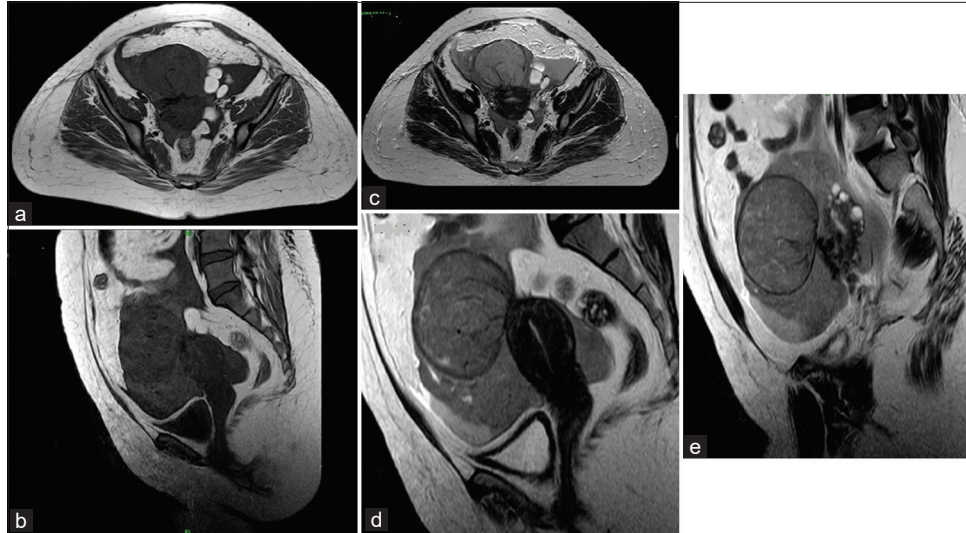


Figure 2: Magnetic resonance imaging (MRI) (a) axial and (b) sagittal section at the level of pelvis shows well-defined pedunculated subserosal T1 iso-hypo intense mass lesion noted, arising from the anterior aspect of uterine fundus. MRI (c) axial and (d) sagittal section at the level of pelvis shows well-defined pedunculated sub-serosal T2 hyperintense mass lesion noted, arising from the anterior aspect of uterine fundus measuring. MRI T2 (e) sagittal section shows well-defined pedunculated sub-serosal fibroid with prominent intralesional flow voids-suggestive of feeding vessels.

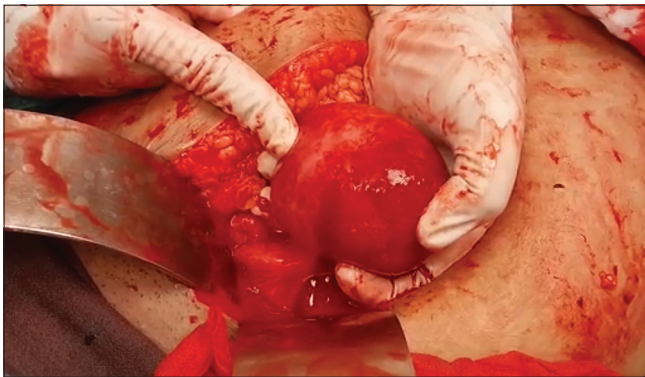


Figure 3: Intraoperative image showing blood ooze from the surface of the fibroid.

ruptured ectopic pregnancy on USG. Demonstration of ring of fire appearance on color Doppler further substantiates tubal ectopic pregnancy.^[7]

Ruptured ovarian cyst is characterized by the irregular appearance of cyst wall with internal septae – cobweb sign.^[8] It often does take up vascularity on color Doppler. Hemorrhagic and endometriotic cysts can be differentiated by MRI with the help of T2 shading sign, seen in endometriosis as dependent hypointense signals within the cyst.^[9,10]

Hemoperitoneum in uterine fibroids is common with subserosal type of fibroids, with a possible cause being the rupture of surface vessels. Although, active arterial contrast extravasation may not be elicited in all cases, significant

hemoperitoneum should not be neglected as it can result in hypovolemic shock.^[3-6]

DIFFERENTIAL DIAGNOSIS

The differential diagnosis is highlighted in Table 1.

Table 1: Differential diagnosis.

Differential diagnosis	Differentiating features
1. Ruptured ectopic pregnancy	- Thickened endometrium - Complex adnexal mass/cyst - Tubal ring sign - Free fluid or hemoperitoneum in pouch of Douglas
2. Ruptured ovarian cyst	- Irregular cyst wall - Internal septae-cobweb sign - Free fluid in pouch of Douglas
3. Ovarian torsion	- Edematous and enlarged ovary - Midline ovarian position - Absent arterial or venous flow - Whirlpool sign of twisted vascular pedicle
4. Leiomyosarcoma	- Heterogeneous lesion with irregular borders and areas of necrosis

CONCLUSION

Being a rare cause of non-traumatic hemoperitoneum, a bleeding leiomyoma should be included in the differential diagnosis especially if it is a larger one. Rapid diagnosis and active

management are essential to treat this potentially life-threatening condition. The definitive treatment in case of hemoperitoneum associated with uterine fibroid is myomectomy but sometimes, hysterectomy may be warranted at the extreme situation.

TEACHING POINTS

1. Fibroids, though being a rare cause of acute abdominal pain with hemoperitoneum, it is important to keep them as differentials among the non-traumatic causes.
2. Imaging plays an important role in differentiation of fibroid from leiomyosarcoma.

MCQs

1. Which of the following can be a cause of obstetric and gynecological non-traumatic hemoperitoneum?
 - a. Ruptured ectopic pregnancy
 - b. Ovarian torsion
 - c. Leiomyoma
 - d. All the above

Answer Key: d

2. Which of the following USG color Doppler signs favors the diagnosis of subserosal fibroid?
 - a. Whirlpool sign
 - b. Bridging vascular sign
 - c. Pedicle sign
 - d. None of the above

Answer Key: b

3. Which of the following is an independent risk factor for rupture of surface veins in leiomyoma?
 - a. Size of the fibroid
 - b. Type of fibroid
 - c. Location of fibroid
 - d. None of the above

Answer Key: a

Ethical approval

Institutional Review Board approval is not required/waived-off.

Declaration of patient consent

Patient's consent not required as patient's identity is not disclosed or compromised.

Financial support and sponsorship

Nil.

Conflicts of interest

There are no conflicts of interest.

Use of artificial intelligence (AI)-assisted technology for manuscript preparation

The authors confirm that there was no use of artificial intelligence (AI)-assisted technology for assisting in the writing or editing of the manuscript and no images were manipulated using AI.

REFERENCES

1. Choi JH, Liu HJ, Heo SM, Kim SA. Hemoperitoneum caused by spontaneous rupture of uterine leiomyoma in a perimenopausal woman. *J Menopausal Med* 2021;27:42-5.
2. Spanoudaki A, Oikonomou A, Dimitrova K, Prassopoulos P. Pedunculated uterine leiomyoma mimicking abdominal mass: A case report. *Cases J* 2008;1:315.
3. Daimon A, Tanaka T, Kogata Y, Tanaka Y, Fujita D, Ohmichi M. Hemoperitoneum associated with uterine fibroids: A case report. *Medicine (Baltimore)* 2021;100:e24024.
4. Elkbuli A, Shaikh S, McKenney M, Boneva D. Life-threatening hemoperitoneum secondary to rupture of a uterine leiomyoma: A case report and review of the literature. *Int J Surg Case Rep* 2019;61:51-5.
5. Hu H, Choi JD, Arrage N. Unusual presentation of hemoperitoneum secondary to ruptured uterine leiomyoma: A case report. *Gynecol Pelvic Med* 2022;5:19.
6. Rokhgireh S, Kashi AM, Kermansaravi M, Tajbakhsh B, Allahqoli L, Alkatout I, *et al.* Hemoperitoneum due to bleeding from a vein overlying a subserous uterine myoma: A case report. *J Med Case Rep* 2020;14:55.
7. Baker M, dela Cruz J. Ectopic pregnancy, ultrasound. In: *StatPearls*. Treasure Island, FL: StatPearls Publishing; 2022.
8. Miele V, Andreoli C, Cortese A, De Cicco ML, Luzietti M, Stasolla A, *et al.* Hemoperitoneum following ovarian cyst rupture: CT usefulness in the diagnosis. *Radiol Med* 2002;104:316-21.
9. Young H, Bui TL, Cramer SE, O'Connell R, Houshyar R. Ruptured endometrioma in a nonpregnant patient: A case report. *J Med Case Rep* 2022;16:161.
10. Sethupathy T, Madathupalayam M, Prasad KA. Intra-abdominal hemorrhagic catastrophe due to large subserous myomatous capsular venous rupture. *Case Rep Obstet Gynecol* 2022;2022:2696213.

How to cite this article: Shanmuga Jayanthan S, Rupesh G, Devipriya T, Nadasadharan K. A rare cause of hemoperitoneum – Gynecological emergency. *Case Rep Clin Radiol*. 2024;2:87-90. doi:10.25259/CRCR_42_2023