

Case Report

Atypical presentation of a cystic parathyroid adenoma: Acute airway compromise secondary to intratumoral apoplexy - A case report

Pravitha Baskar¹, Sriman Rajasekaran¹, Swathigha Selvaraj¹, Venkatesh Kasi Arunachalam¹, P. S. Shobhanaa²

Departments of ¹Radiodiagnosis and ²Pathology, Kovai Medical Center and Hospital, Coimbatore, Tamil Nadu, India.

*Corresponding author:

Venkatesh Kasi Arunachalam,
Department of Radiodiagnosis,
Kovai Medical Center and
Hospital, Coimbatore,
Tamil Nadu, India.

drkasivenkatesh@yahoo.co.in

Received: 18 March 2023
Accepted: 17 May 2023
Epub Ahead of Print: 07 June 2023
Published: 13 July 2024

DOI
10.25259/CRCR_41_2023

Quick Response Code:



ABSTRACT

Spontaneous hemorrhage into cystic parathyroid lesion is a very rare and life-threatening complication which poses diagnostic challenge to the clinician as well as the radiologist due to various close mimics. Prompt identification, diagnosis, and emergent treatment are imperative to save the life of the patient. We report a case of a 56-year-old female who presented with acute airway compromise due to a giant cystic parathyroid adenoma with spontaneous hemorrhage. Magnetic resonance imaging was performed, and the patient underwent surgical exploration.

Keywords: Cystic lesion, Parathyroid adenoma, Intratumoral apoplexy, Airway compromise

INTRODUCTION

Primary hyperparathyroidism is the common presentation of parathyroid adenomas. Parathyroid adenomas weighing >3.5 g and having a size of more than 2 cm are termed as giant parathyroid adenomas. Most adenomas are asymptomatic; however, giant adenomas can cause anatomical symptoms which can manifest as dysphagia, odynophagia, and dyspnea. Hemorrhage into a giant parathyroid adenoma is a rare presentation that can be life threatening due to acute airway compromise.^[1]

CASE REPORT

A 56-year-old female who has been a known diabetic for 8 years and hypothyroidism for 6 years, on medication, presented to the hospital with acute onset of breathlessness and stridor. She also has a history of anterior neck swelling for 2 years. Complete blood count and serum electrolytes were normal. Serum creatinine was 0.6 mg/dL. Serum calcium was 8.7 mg/dL and phosphorus was 2.8 mg/dL, free triiodothyronine - 2.7 pg/mL; Free Thyroxine - 1.32 ng/mL, and TSH - 3.7 μU/mL. The patient underwent non-contrast computed tomography neck and thorax on December 8, 2022. CT revealed multiloculated soft-tissue attenuation lesion with hemorrhage in post-cricoid region with extension into superior mediastinum. Fibro-optic laryngoscopy was performed on the same day and was normal.

The patient was planned for emergency bronchoscopy and tracheal stenting, but due to severe distress with glasgow coma scale score (GCS) drop, she was intubated and shifted to magnetic resonance imaging (MRI).

This is an open-access article distributed under the terms of the Creative Commons Attribution-Non Commercial-Share Alike 4.0 License, which allows others to remix, transform, and build upon the work non-commercially, as long as the author is credited and the new creations are licensed under the identical terms.

©2024 Published by Scientific Scholar on behalf of Case Reports in Clinical Radiology

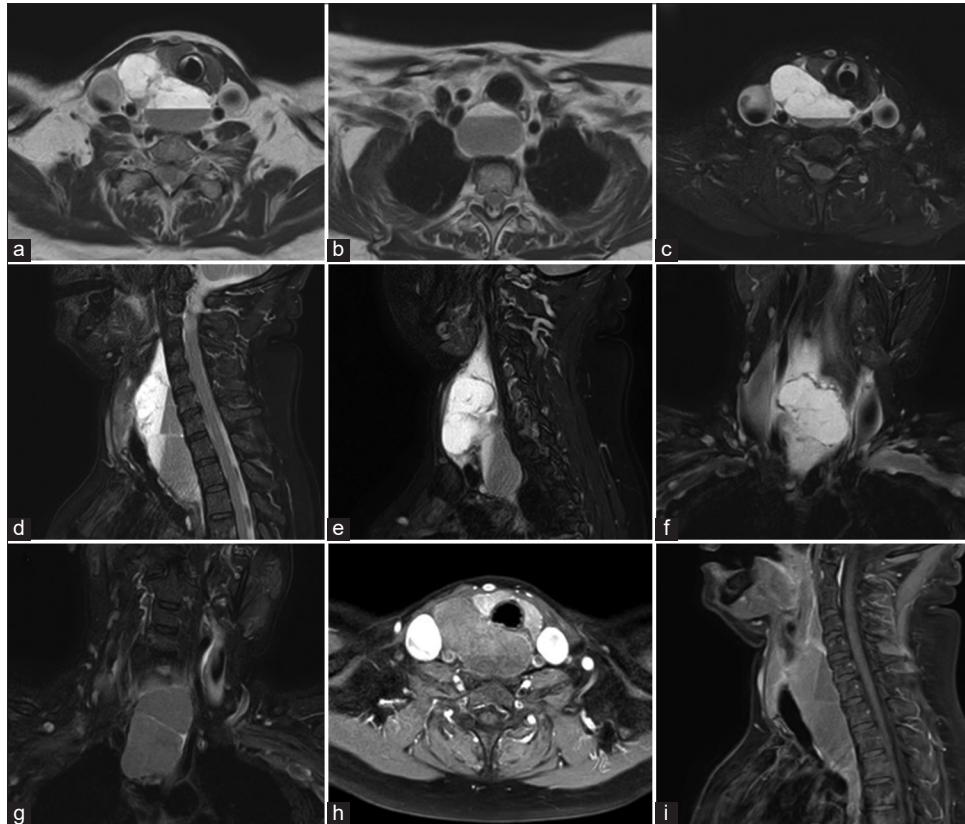


Figure 1: Axial T2-weighted (a and b) and fat-saturated images (c) of lower neck and upper mediastinum reveals a multiloculated T2 hyperintense lesion with blood-fluid levels which is posterior to the right lobe of thyroid and extending to superior mediastinum. T2 fat sat sagittal (d and e) and coronal (f and g) images shows the craniocaudal extent of the lesion with clear demonstration of the internal hemorrhage. T1 post-contrast axial (h) and sagittal (i) sections show peripheral rim of enhancement and clear demonstration of the relationship to the right lobe of thyroid.

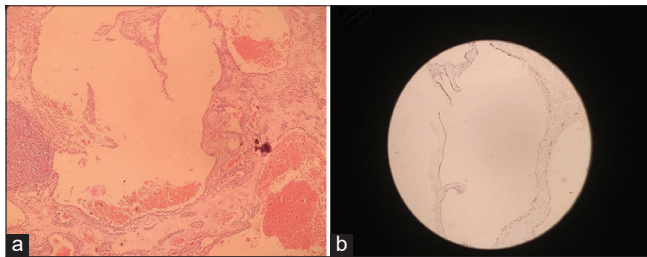


Figure 2: (a) $\times 10$ H and E shows multiple cystic space with hemorrhage lined by attenuated epithelium and on the left shows nest of parathyroid chief cells. (b) $\times 10$ immunohistochemistry with pancytokeratin highlights epithelium lining cystic spaces. H and E: Hematoxylin and eosin.

The patient underwent a contrast-enhanced MRI neck on December 9, 2022. MR images showed a well-defined multiloculated cystic lesion with blood-fluid levels in the lower neck in the post-cricoid region. The lesion was predominantly in the midline with right para-pharyngeal extension. The lesion was extending inferiorly to the superior mediastinum. Craniocaudally, the lesion extends from C4 to

the D2 level. Mediolaterally, the lesion is seen between the carotid arteries posterior to the laryngeal airway; a small component of the lesion extends into the right lateral aspect of the neck, splaying the thyroid cartilage and jugular vein and lies immediately deep to sternocleidomastoid [Figure 1]. The lesion abuts the posterior wall of the trachea and esophagus and causes the displacement of the laryngeal airway anteriorly and to the left. The lesion is inseparable from the posterior aspect of the right lobe of the thyroid and esophagus. Posteriorly, the lesion abuts the anterior vertebral margin without any significant indentation. The lesion shows T1 intermediate and T2 hyperintense signals. Based on the patient's age, imaging characteristics, and clinical history, the possibilities of venous-lymphatic malformation and esophageal duplication cyst with internal hemorrhage were considered as top differentials.

The patient underwent surgery and an excision biopsy of the cyst wall on December 10, 2022. The patient was discharged in stable condition on the 5th postoperative day. In a histopathological and immunohistochemical examination

of the surgical specimen, a cystic parathyroid adenoma with extensive hemorrhage was diagnosed [Figure 2].

DISCUSSION

Cystic parathyroid adenomas account for a small proportion - 1–4% of all parathyroid adenomas.^[2] Parathyroid cystic adenomas are traditionally classified as functioning and non-functioning and may represent up to 5% of cystic tumors in the anterior region of the neck. Approximately, 90% of these are classified as non-functioning cystic lesions found in individuals with normal calcium concentrations.

Cystic parathyroid adenomas are associated with large lesions, high-serum levels of intact parathyroid hormone and calcium, a high risk of hypercalcemic crisis, and low accuracy of preoperative localization examinations. Current standard modalities for imaging parathyroid lesions include ultrasound, Tc99m-sestamibi, 4-dimensional CT, and MRI.^[3] The preoperative diagnosis of cystic parathyroid adenomas remains challenging. Combined ultrasound and Sestamibi scan has high diagnostic accuracy for solid adenomas, but the accuracy is low for cystic lesions.^[4]

Spontaneous parathyroid hemorrhage is a rare but potentially life-threatening complication of parathyroid disease. The possibility of hemorrhage in parathyroid lesions should be considered in anyone presenting with retropharyngeal or mediastinal hemorrhage, mainly if there is a documented history of hyperparathyroidism.

Nylen *et al.* proposed the classification of parathyroid apoplexy into

- Type I: Adenoma with necrosis without hemorrhage
- Type II: Adenoma with intracapsular hemorrhage and necrosis
- Type III: Adenoma with extracapsular hemorrhage.^[5]

Clinical presentations also vary in each group. The patient may be asymptomatic or experience gastrointestinal discomfort, cervical pain, tetany, and convulsions in adenoma with intracapsular hemorrhage.^[6] Acute pain, dysphagia, dysphonia, hoarseness, stridor, hypercalcemic crisis, widened mediastinum, visible hematoma, or ecchymosis may occur in patients with extracapsular hemorrhage. The definite treatment of parathyroid adenoma is surgical exploration.^[7]

DIFFERENTIAL DIAGNOSIS

1. Venolymphatic malformation.
2. Esophageal duplication cyst with internal hemorrhage.

CONCLUSION

Emergency intervention and neck exploration may be required in cases of airway compromise. In the literature,

there is evidence that hemorrhage into the lesion leads to spontaneous remission of hyperparathyroidism. This phenomenon is referred to as auto parathyroidectomy/parathyroid apoplexy. The normal calcium levels in our case can be attributed to either non-functioning adenoma/phenomenon of auto parathyroidectomy.

TEACHING POINTS

1. Parathyroid apoplexy should be considered in any patient with spontaneous cervical hemorrhage which aids in pre-operative planning and avoidance of unnecessary delay in diagnosis and treatment.
2. Initial evaluation of patients with spontaneous cervical hemorrhage should include imaging, serum calcium, and PTH assay.

MCQs

1. What are the standard modalities for imaging parathyroid lesions
 - a. Ultrasound
 - b. Tc99m-sestamibi
 - c. 4-dimensional CT
 - d. MRI
 - e. All of the above

Answer Key: e

2. Which is the sensitive radiological modality in detecting solid parathyroid adenomas?
 - a. Ultrasound and CECT
 - b. CECT and CE MRI
 - c. USG and MIBI scan
 - d. MRI and MIBI scan

Answer Key: c

3. Nylen classification of parathyroid apoplexy consists of
 - a. 3 Types
 - b. 4 Types
 - c. 5 Types
 - d. 6 Types

Answer Key: a

Ethical approval

Institutional Review Board approval is not required/waived-off.

Declaration of patient consent

Patient's consent not required as patients identity is not disclosed or compromised.

Financial support and sponsorship

Nil.

Conflicts of interest

There are no conflicts of interest.

Use of artificial intelligence (AI)-assisted technology for manuscript preparation

The authors confirm that there was no use of artificial intelligence (AI)-assisted technology for assisting in the writing or editing of the manuscript and no images were manipulated using AI.

REFERENCES

1. Garrahy A, Hogan D, O'Neill JP, Agha A. Acute airway compromise due to parathyroid tumour apoplexy: An exceptionally rare and potentially life-threatening presentation. *BMC Endocr Disord* 2017;17:35.
2. Johnson NA, Yip L and Tublin ME. Cystic parathyroid adenoma: sonographic features and correlation with ^{99m}Tc-sestamibi SPECT findings. *AJR Am J Roentgenol* 2010;

- 195(6):1385-90.
3. Johnson NA, Tublin ME, Ogilvie JB. Parathyroid imaging: Technique and role in the preoperative evaluation of primary hyperparathyroidism. *AJR Am J Roentgenol* 2007;188:1706-15.
4. Smith JR, Oates ME. Radionuclide imaging of the parathyroid glands: Patterns, pearls, and pitfalls. *Radiographics* 2004;24:1101-15.
5. Efremidou EI, Papageorgiou MS, Pavlidou E, Manolas KJ, Liratzopoulos N. Parathyroid apoplexy, the explanation of spontaneous remission of primary hyperparathyroidism: A case report. *Cases J* 2009;2:6399.
6. Wieneke JA, Smith A. Parathyroid adenoma. *Head Neck Pathol* 2008;2:305-8.
7. Majcen M, Hocevar M. Surgical options in treating patients with primary hyperparathyroidism. *Radiol Oncol* 2020;54(1):22-32.

How to cite this article: Baskar P, Rajasekaran S, Selvaraj S, Arunachalam VK, Shobhanaa P. Atypical presentation of a cystic parathyroid adenoma: Acute airway compromise secondary to intratumoral apoplexy - A case report. *Case Rep Clin Radiol.* 2024;2:128-31. doi: 10.25259/CRCR_41_2023