

Case Report

Cecal duplication cyst in an adult: A case report

Bhaven Shah¹, Rahulkumar S. Vasava¹, Aditya Patel¹, Muskan Jain¹

¹Department of Radiology, Gujarat Adani Institute of Medical Sciences, Bhuj, Gujarat, India.

*Corresponding author:

Rahulkumar S. Vasava,
Department of Radiology,
Gujarat Adani Institute of
Medical Sciences, Bhuj, Gujarat,
India.

rspace72@gmail.com

Received: 21 January 2024
Accepted: 06 March 2024
Epub Ahead of Print: 29 April 2024
Published:

DOI

10.25259/CRCR_7_2024

Quick Response Code:



ABSTRACT

Enteric duplication cysts are rare congenital malformations and cecal duplication cysts are rarer which develop only in 0.4% of cases of gastrointestinal tract duplication and only 43 cases have been reported in literature to date. The ileum and ileocecal junction are among the most common sites. We hereby report a case of a 50-year-old female who presented with signs and symptoms of acute intestinal obstruction that was clinically and radiologically interpreted as volvulus for which the patient underwent resection of the cyst and ileocecal anastomosis and was then histopathologically confirmed as cecal duplication cyst.

Keywords: Cecal duplication cyst, Intestinal obstruction, Computed tomography, Volvulus

INTRODUCTION

Duplication cysts of the gastrointestinal tract are rare and cecal duplication cysts are rarer. Cecal duplication cysts are most commonly present within the first 2 years of life, but some rare cases may remain asymptomatic during childhood and may present in adult life.^[1] The clinical picture may vary according to the location, size, and type of the cyst. The most common symptoms of duplication cysts are that of an acute abdomen and are, therefore, very difficult to diagnose clinically.

In this article, we present an infrequent case of a cecal duplication cyst, which is itself rare, and presenting in adulthood is among the rarest phenomena. We address that the index of suspicion for a rare entity of duplication cyst should be kept in mind when the proximal loops are not dilated, but the patient has clinical and radiological signs of intestinal obstruction.

CASE REPORT

This is a case of 50-year-old female who presented to the emergency department of our hospital in September 2023 with chief complaints of palpable abdominal lump and progressive abdominal distension, abdominal pain in the right iliac fossa region. Along with this, the patient had symptoms of constipation, vomiting, abdominal fullness, tenderness, and palpitations. The patient had a history of constipation and post-prandial abdominal fullness and nausea for the last 15–20 years, for which she was taking medications for symptomatic relief. She has also been hospitalized several times for weakness, constipation, and nausea in the last 20 years. There are no comorbidities and significant family history associated.

This is an open-access article distributed under the terms of the Creative Commons Attribution-Non Commercial-Share Alike 4.0 License, which allows others to remix, transform, and build upon the work non-commercially, as long as the author is credited and the new creations are licensed under the identical terms.

©2024 Published by Scientific Scholar on behalf of Case Reports in Clinical Radiology

On physical examination, the pulse rate was 120/min, blood pressure was 90/60 mmHg, temperature was 38°C, respiratory rate was 20/min, and oxygen saturation was 99% in room air. On systemic examination, there was abdominal distension, tenderness in the right lumbar region and right iliac fossa, and palpable abdominal mass in the right-sided abdominal region. Blood investigations revealed a total white blood cell count of 8,610/cu mm with mild neutrophilia, lymphocytosis and monocytosis, and hemoglobin of 11.5 g/dL. Radiograph of the abdomen in an erect position showed no significant abnormality. Ultrasound of the abdomen showed a gaseous abdomen. Bowel obstruction could not be ruled out. Contrast-enhanced computed tomography (CT) of the abdomen: Grossly dilated caecum measuring approximately 20 cm in transverse diameter extending up to the right dome of the diaphragm, the possibility of cecal volvulus. Other differentials: Diverticulum/duplication cyst [Figure 1].

As the patient was diagnosed with cecal volvulus, she was taken for emergency exploratory laparotomy. Intraoperatively, a large cecal diverticulum with blind-ended huge colonic fecal matter-filled cystic lesion was identified for which resection of a huge diverticulum with ileocolic resection and ileotransverse anastomosis was done [Figure 2]. The patient was hemodynamically stable after the surgery. The patient was discharged from the hospital on the 7th post-operative day without any remarkable post-operative events. Histopathological examination revealed features suggestive of cystic duplication of the colon without any granulomatous, inflammatory bowel disease, or malignant pathology. On follow-up visit after one month, the patient is quite happy and satisfied now.

DISCUSSION

Gastrointestinal duplication cysts are rare congenital anomalies and may occur in any part of the esophagus to the anus and are attached to the mesenteric side of the bowel.^[2]

Enteric duplication cysts are true diverticula of the bowel. They comprise an enteric mucosa, a muscle layer, and a nervous plexus.^[3]

Duplication cysts are embryological aberrations that are believed to occur between the 4th and 8th weeks of gestation, although the exact cause is not known. The following theories have been proposed to explain its etiopathogenesis: According to the split notochord theory, duplication cysts are abnormal separation of the growing notochord from the endodermal cells. This theory explains the association of vertebral anomalies with the duplication cysts.^[4] According to the recanalization theory, duplication cysts occur due to errors in the recanalization of the gut. According to the embryonic diverticula theory, a preexisting diverticula in the embryo grows with the growth of the alimentary tract which results in the development of duplication cysts. This theory

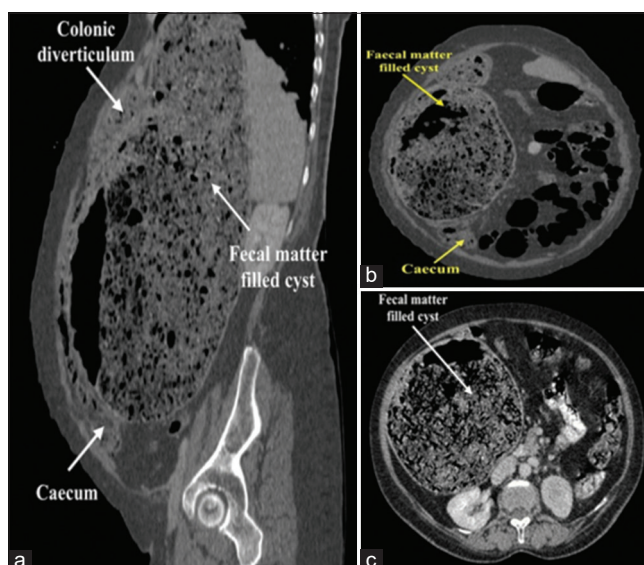


Figure 1: 3D multi-planar reconstruction of computed tomography images on oblique sagittal, coronal, and axial plane with labelings. (a) sagittal view - top white arrow: colonic diverticulum, middle white arrow: fecal matter filled cyst, bottom white arrow: caecum. (b) Coronal view - top yellow arrow: fecal matter filled cyst, bottom yellow arrow: Caecum. (c) Axial view: white arrow - fecal matter filled cyst.

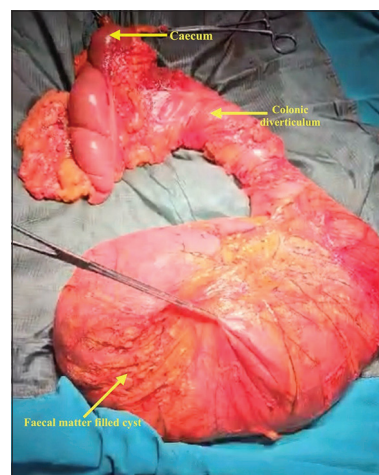


Figure 2: Specimen after ileocecal resection showing a blind-ended fecal matter-filled cyst. top yellow arrow: caecum, middle yellow arrow: colonic diverticulum, bottom yellow arrow: fecal matter filled cyst.

is quite justifiable but is unable to explain the presence of heterotopic mucosa in these cysts.^[4,5]

The duplication cysts can be diagnosed by ultrasonography (USG), CT, magnetic resonance imaging, and technetium pertechnetate scan. The double wall sign in USG has high specificity and positive predictive value still, it is quite subjective and difficult to distinguish from intussusception,

Table 1: Differential diagnosis of cecal duplication cyst.

	Cecal duplication cyst	Volvulus	Intussusception	Meckel's diverticulum
Radiograph findings	May be normal or may show changes of intestinal obstruction (Erect Radiograph abdomen: multiple air-fluid levels, dilated bowel loops).	Dilated bowel loops >9 cm in case of cecal volvulus.	Multiple air-fluid levels in proximal bowel loops and distally collapsed bowel loops.	--
USG findings	Hyperechoic wall of cyst/Double wall sign.	Whirlpool sign	Target/doughnut sign	Blind ending peristaltic loop connected to the small bowel.
CT findings	Dilated bowel loops/diverticulum adjacent to caecum containing fluid/fecal matter.	Bird beak sign	Bowel within bowel configuration	Fluid or air-filled blind-ending pouch that arises from the antimesenteric border of the distal ileum.

CT: Computed tomography, USG: Ultrasonography

volvulus, etc.^[6] However, CT remains the most effective modality to diagnose duplication cysts. In our case, it was difficult to distinguish between cecal volvulus and cecal duplication cyst. Surgical removal is the mainstay of treatment. Resection of the involved segment followed by end-to-end anastomosis is preferred for small cysts. For the larger cysts, where the segment involved is extensive and tubular, procedures such as enucleation, marsupialization, and excision of the mucosal layer are preferred to preserve the bowel length.^[7-9] Even in our case, the cyst was resected and then ileocecal anastomosis was preferred. Even after huge advancements in ultrasound imaging, only 20–30% of cases are being diagnosed antenatally.

DIFFERENTIAL DIAGNOSIS

Differential diagnoses of cecal duplication cyst can be cecal volvulus, meckel's diverticulum, and intussusception. The distinguishing features are described in Table 1.

CONCLUSION

Cecal duplication cysts are rare congenital anomalies and difficult to diagnose as they present variably and have multiple differential diagnoses. Therefore, it is important to consider it in differentials when the patient presents with symptoms of acute abdomen. Although radiological investigations such as USG and CT are quite reliable, confirmatory diagnosis is made by histopathological examination.

TEACHING POINTS

1. Cecal duplication cysts commonly present early in life, but in some rare cases, they can even present later, and thus, it is important to consider it in differentials of acute abdomen.
2. Although the histopathological examination is best for confirmation of diagnosis, radiological modalities help in narrowing down the differentials and thus help in planning the line of management preoperatively.

MCQs

1. Which is the most effective radiological modality to diagnose a cecal duplication cyst?
 - a) CT
 - b) Ultrasonography
 - c) Radiography
 - d) MRI

Answer Key: a

2. Which is the most common site for enteric duplication cysts?
 - a) Cecum
 - b) Rectum
 - c) Ileum
 - d) Colon

Answer Key: c

3. Which is the gold standard investigation to diagnose a cecal duplication cyst?
 - a) CT
 - b) MRI
 - c) Histopathological examination
 - d) Ultrasonography

Answer Key: c

Acknowledgments

The patient was operated by Dr. Mahesh Thacker. and Dr. Shivam Kotak guided us.

Ethical approval

Institutional Review Board approval is not required.

Declaration of patient consent

The authors certify that they have obtained all appropriate patient consent.

Financial support and sponsorship

Nil.

Conflicts of interest

There are no conflicts of interest.

Use of artificial intelligence (AI)-assisted technology for manuscript preparation

The authors confirm that there was no use of artificial intelligence (AI)-assisted technology for assisting in the writing or editing of the manuscript and no images were manipulated using AI.

REFERENCES

1. Liu R, Adler DG. Duplication cysts: Diagnosis, management, and the role of endoscopic ultrasound. *Endosc Ultrasound* 2014;3:152.
2. Shetty T, Chavan K. Laparoscopic right hemicolectomy for rare case of caecal duplication cyst manifested as intussusception in an adult: A case report. *Int Surg J* 2022;9:1656-8.
3. Stoupis C, Ros PR, Abbitt PL, Burton SS, Gauger J. Bubbles in the belly: Imaging of cystic mesenteric or omental masses. *Radiographics* 1994;14:729-37.
4. Sangüesa Nebot C, Llorens Salvador R, Carazo Palacios E, Picó Aliaga S, Ibañez Pradas V. Enteric duplication cysts in children: Varied presentations, varied imaging findings. *Insights Imaging* 2018;9:1097-106.
5. Pant N, Grover JK, Madan NK, Chadha R, Agarwal K, Choudhury SR. Completely isolated enteric duplication cyst associated with a classic enterogenous duplication cyst. *J Indian Assoc Pediatric Surg* 2012;17:68.
6. Verma S, Bawa M, Rao KL, Sodhi KS. Caecal duplication cyst mimicking intussusception. *Case Rep* 2013;2013:bcr2012008056.
7. Saxena R, Pathak M, Sinha A. Caecal duplication cyst: A rare disease with variable presentation and its management in the era of laparoscopy. *J Minim Access Surg* 2020;16:71-3.
8. Radhakrishna V, Rijhwani A, Jadhav B. Cecal duplication: A mimicker of intussusception: A case report and review. *Ann Med Surg* 2018;31:17-9.
9. Oudshoorn JH, Heij HA. Intestinal obstruction caused by duplication of the caecum. *Eur J Pediatr* 1996;155:338-40.

How to cite this article: Shah B, Vasava RS, Patel A, Jain M. Cecal duplication cyst in an adult: A case report. *Case Rep Clin Radiol*. doi: 10.25259/CRCR_7_2024