

## Case Report

# An intriguing case of acute abdomen secondary to ruptured pyomyoma: A case report

Greta Vincent<sup>1</sup>, Vandana Sudheer<sup>1</sup>, Anusha Varghese<sup>1</sup>, George Joseph<sup>1</sup>

<sup>1</sup>Department of Radiology, Lourdes Hospital (Post Graduate Institute of Medical Science and Research), Kochi, Kerala, India.

### \*Corresponding author:

Greta Vincent,  
Department of Radiology,  
Lourdes Hospital (Post  
Graduate Institute of Medical  
Science and Research), Kochi,  
Kerala, India.

mizgr8a@gmail.com

Received: 10 May 2023  
Accepted: 05 June 2023  
Epub Ahead of Print: 24 June 2023  
Published:

### DOI

10.25259/CRCR\_88\_2023

### Quick Response Code:



## ABSTRACT

Pyomyoma by definition is a suppurative leiomyoma, as a result of infection of infarcted leiomyoma. Pyomyoma is a gynecological emergency as it can further lead to sepsis and peritonitis resulting in high morbidity and mortality. A high index of clinical suspicion is crucial in the diagnosis, and prompt treatment in the initial stage is recommended to reduce mortality. Ultrasound, computed tomography, and magnetic resonance provide diagnostic clues. We present a case of a 44-year-old woman who presented with an acute abdomen due to a spontaneous rupture of pyomyoma. The patient was treated with total abdominal hysterectomy and salpingo-oophorectomy along with peritoneal irrigation and drainage.

**Keywords:** Pyomyoma, Rupture, Fibroid degeneration, Leiomyoma infarction, Peritonitis, Diagnosis

## INTRODUCTION

Large uterine leiomyoma following necrosis with superimposed infection results in the condition known as pyomyoma. The causes for necrotic degeneration of leiomyoma are mainly twofold. Gradual increase in size will make the leiomyoma outgrow its blood supply. This in turn leads to different types of degeneration namely hyaline, myxoid, cystic, or red degeneration.<sup>[1]</sup> Second, exophytic subserosal leiomyoma which project into the abdominal cavity can become pedunculated and undergo torsion resulting in infarction. Red or carneous degeneration and uterine artery embolization associated degeneration results from venous thrombosis along the periphery of a leiomyoma leading to infarction.<sup>[2]</sup>

Most women with leiomyomas are asymptomatic, however, 20%–50% of them have symptoms such as menorrhagia, pelvic pain and infertility, or complications during pregnancy.<sup>[3]</sup> Fatal complications of leiomyoma include torsion, infarction with superimposed infection, and sarcomatous transformation.

The diagnosis of pyomyoma is challenging and the high mortality rate is due to delayed diagnosis. We present an unusual case of pyomyoma which underwent spontaneous rupture resulting in peritonitis and sepsis.

## CASE PRESENTATION

A middle aged female presented to the gynecology department with a 3-day history of lower abdominal pain. She was normally fit and well with a history of fever for 2 days 1 week back followed

This is an open-access article distributed under the terms of the Creative Commons Attribution-Non Commercial-Share Alike 4.0 License, which allows others to remix, transform, and build upon the work non-commercially, as long as the author is credited and the new creations are licensed under the identical terms.

©2023 Published by Scientific Scholar on behalf of Case Reports in Clinical Radiology

by abdominal pain for which an ultrasound (US) scan done elsewhere suggested a tubo-ovarian abscess. She was treated conservatively with intravenous meropenem and other medications at a local hospital. When her symptoms failed to resolve, she was referred to our hospital for further management. No history of vaginal discharge, dysmenorrhea, or dyspareunia. Her menstrual cycles were regular. Her obstetric history was unremarkable with one normal vaginal delivery, 17 years ago and insertion of intrauterine Copper-T 7 years back which was not removed. She did not have any known personal or family history of gynecological problems. She was not on any regular medication. No previous history of surgical intervention.

General examination was unremarkable. Abdominal examination revealed a 7 × 6 cm pelvic mass, with an irregular surface, firm in consistency in the right iliac fossa with mild tenderness. Routine blood results revealed elevated levels of inflammatory markers.

Multiplanar magnetic resonance imaging of the pelvis was performed at 1.5 Tesla system using a body coil and large field of view. The study revealed an enlarged uterus deviated toward the left with multiple intramural and subserous fibroids, the largest of these in the right lateral uterine wall showing altered signal characteristics. This fibroid measured 7.2 × 5.9 × 5.7 cm and demonstrated heterogeneously T2 hypointense, T1 isointense signals. The periphery of this fibroid was T2 hyperintense and T1 hypointense with diffusion restriction. These findings suggested the contents of

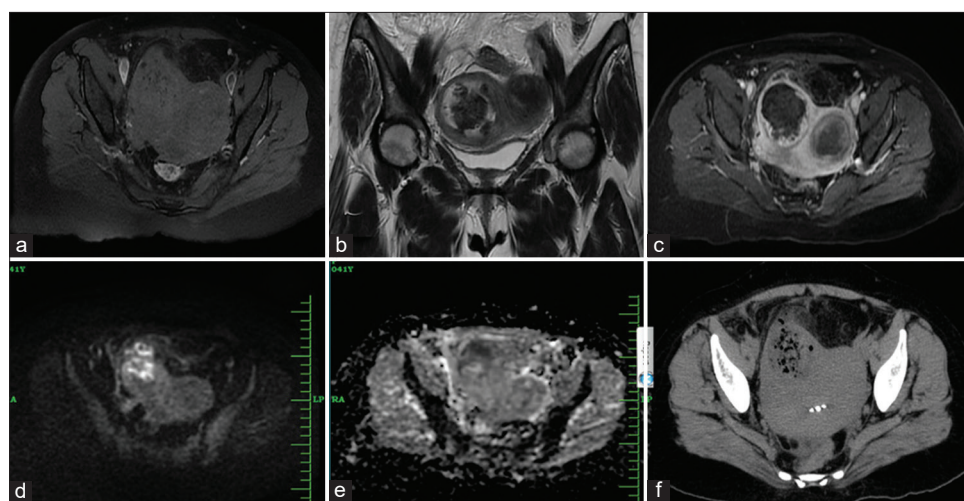
the fibroid were dense fluid compatible with pus. Numerous T1 speckled hypointense areas were noted within.

Post intravenous gadolinium administration, central non-enhancing areas with peripheral thick enhancement was noted in the degenerated fibroid. Small focal area of serosal breach was noted at the highest point along the anterolateral aspect toward the right side. This was demonstrated as multiple small pockets of air in the peritoneal cavity just adjacent to the serosal breach, surrounding fat stranding was also seen. These features were consistent with ruptured pyomyoma and localized peritonitis [Figure 1].

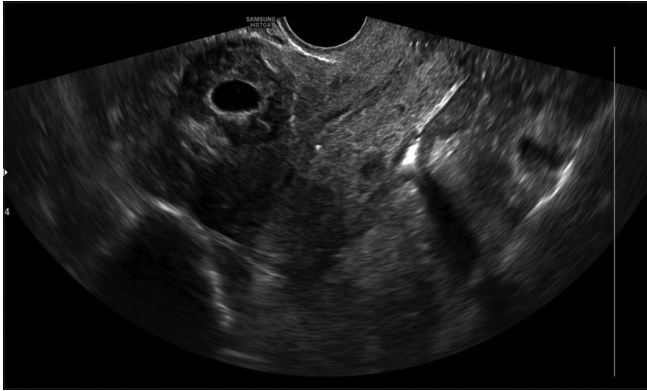Dynamic imaging showed central delayed enhancement of the rest of the fibroids. Intrauterine contraceptive device was noted *in situ*. No adnexal mass lesions were present. Trace-free fluid was seen in pouch of douglas (POD). Correlative transvaginal ultrasonography revealed fibroid with cystic changes [Figure 2].

Intravenous meropenem and metronidazole were initiated, and total hysterectomy with bilateral salpingectomy was performed.

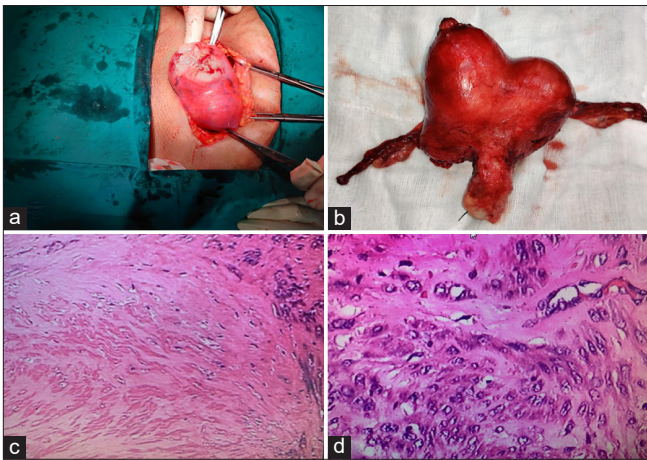
During the surgical intervention, omental adhesions were noted over the anterolateral fundal fibroid with a serosal breach. Purulent material was observed oozing from the opening. The round ligament was stretched over the degenerated fibroid. Inflammatory changes were seen in the caecum, large bowel, and rectovaginal area with omental adhesions [Figure 3].



**Figure 1:** (a) Axial T1 weighted fat suppressed (FS) image showing the multiple heterogeneously hypointense uterine fibroids with speckled hypointense areas in the right lateral fibroid. (b) Coronal T2 weighted image showing heterointense contents of right lateral fibroid. (c) Axial T1 FS Post contrast image showing the degenerated fibroid in the right lateral wall with a necrotic center. (d) Axial diffusion weighted imaging showed hyperintense periphery of the right lateral fibroid with a breach in serosa and hyperintense areas in the adjacent peritoneum. (e) Corresponding apparent diffusion coefficient (ADC) image showing low ADC values in the hyperintense areas consistent with pus. (f) Correlative computed tomography sections showed air pockets corresponding to the mottled appearance with evidence of breach in serosa anteriorly and adjacent fat stranding. Incidental note of intrauterine contraceptive device is made.



**Figure 2:** Correlative transvaginal ultrasound image demonstrates right lateral fibroid with cystic changes.



**Figure 3:** (a) Intraoperative image showing omental adhesions over anterolateral fundal fibroid with serosal breach. Purulent material was observed oozing from the opening. (b) Gross examination of the surgical specimen identified a heterogeneous intramural lesion with yellowish and hemorrhagic areas. (c and d) Histopathological examination confirmed an intramural leiomyoma with large areas of hyalinization and hyalinising necrosis.

Gross examination of the surgical specimen identified a heterogeneous intramural lesion with yellowish and hemorrhagic areas.

Peritoneal fluid cytology smears showed reactive mesothelial cells and inflammatory cells in a background of blood-stained smear confirming localized peritonitis.

Following surgery, there was rapid improvement in the patient's condition and the laboratory results returned to normal. The patient was stable on discharge.

## DISCUSSION

Pyomyoma, or suppurative leiomyoma, is a rare entity which occurs due to infection of a leiomyoma. The infected

leiomyoma generally shows suppurative inflammation, containing pus with neutrophils and necrotic exudate.<sup>[4]</sup>

Most cases of premenopausal pyomyoma have occurred following abortion or delivery mainly caused by ascending infection from the lower genital tract.<sup>[5]</sup> These cases have also been reported following uterine instrumentation or as a result of cervical stenosis.<sup>[6]</sup> Pyomyomas that develop in postmenopausal women are presumably caused by ischemia resulting from hypertension, diabetes, or atherosclerosis.<sup>[7]</sup>

Imaging plays an important role in the diagnosis of pyomyomas. Computed tomography (CT) and US are the usual first-line imaging tests in patients with suspected gynecological or abdominal infections who present at the emergency department; however, their findings in patients with pyomyomas are usually nonspecific. US generally shows a heterogeneous uterine or parauterine mass with a cystic component.<sup>[4]</sup> CT usually shows a solid-cystic lesion associated with pelvic inflammatory signs. The presence of gas within the lesion due to the presence of gas-producing microorganisms is a specific but uncommon sign for pyomyoma.<sup>[8]</sup>

However, MRI in particular diffusion-weighted imaging sequence is preferred to CT to clinch the diagnosis. In our case, the location of the pus was peripheral in contrast to intratumoral abscess/necrosis, in which the area of abscess formation usually has a central distribution.<sup>[9]</sup>

The differential diagnosis of a pelvic mass with a clinical presentation suggestive of infection includes endometritis, pyometra, tubo-ovarian abscess, complicated gynecological neoplasm, and pyomyoma.<sup>[10]</sup> Delayed diagnosis or untreated or inappropriately treated pyomyoma can result in peritonitis and high mortality.

## CONCLUSION

We have presented a case of spontaneous rupture of pyomyoma with resultant localized peritonitis. This case highlights the importance of urgent MR evaluation for pre and postmenopausal women presenting with acute abdominal pain with pelvic mass suspicious for pyomyoma and the need for prompt management to prevent mortality and morbidity.

## TEACHING POINTS

- Large uterine leiomyoma following necrosis with superimposed infection results in pyomyoma. Delayed diagnosis results in high mortality, thus early identification is the key.
- The presence of gas within the fibroid in CT imaging is a specific but uncommon sign for pyomyoma. DWI sequences in MRI are crucial to clinch the diagnosis.

The location of the gas is peripheral which appears as numerous T1 speckled hypointense areas.

### MCQs

1. Pyomyoma in post-menopausal women is presumably caused by ischemia resulting from:
  - a. Hypertension
  - b. Diabetes
  - c. Atherosclerosis
  - d. All of the above

Answer Key: d

2. The presence of gas in leiomyoma is indicative of
  - a. Pyomyoma
  - b. Necrotic degeneration
  - c. Hyaline degeneration
  - d. Red degeneration

Answer Key: b

3. Routes of infection leading to pyomyoma include:
  - a. Contiguous spread from the endometrial cavity
  - b. Direct extension from bowel or adnexa
  - c. Hematogenous or lymphatic spread of infection from elsewhere
  - d. All of the above

Answer Key: d

### Acknowledgments

We would like to thank Dr. Binu Sebastian, consultant gynecologist and laparoscopic surgeon and Dr. Shamla Backer, resident in gynecology for their valuable contributions and the intraoperative images presented in this case. Our sincere gratitude to Dr. Priya Mariam Kuruvilla for her assistance and expertise in curating the histopathological images presented in this case.

### Declaration of patient consent

Patient's consent not required as patients identity is not disclosed or compromised.

### Financial support and sponsorship

Nil.

### Conflicts of interest

There are no conflicts of interest.

### REFERENCES

1. Sue W, Sarah SB. Radiological appearances of uterine fibroids. *Indian J Radiol Imaging* 2009;19:222-31.
2. DeMulder D, Ascher SM. Uterine leiomyosarcoma: Can MRI differentiate leiomyosarcoma from benign leiomyoma before treatment? *Am J Roentgenol* 2018;211:1405-15.
3. Murase E, Siegelman ES, Outwater EK, Perez-Jaffe LA, Tureck RW. Uterine leiomyomas: Histopathologic features, MR imaging findings, differential diagnosis, and treatment. *Radiographics* 1999;19:1179-97.
4. Read S, Mullins J. Spontaneous ruptured pyomyoma in a nulligravid female: A case report and review of the literature. *Case Rep Obstet Gynecol* 2018;2018:1026287.
5. Kobayashi F, Kondoh E, Hamanishi J, Kawamura Y, Tatsumi K, Konishi I. Pyomyoma during pregnancy: A case report and review of the literature. *J Obstet Gynaecol Res* 2013;39:383-9.
6. Iwahashi N, Mabuchi Y, Shiro M, Yagi S, Minami S, Ino K. Large uterine pyomyoma in a perimenopausal female: A case report and review of 50 reported cases in the literature. *Mol Clin Oncol* 2016;5:527-31.
7. Karcaaltincaba M, Sudakoff GS. CT of a ruptured pyomyoma. *Am J Roentgenol* 2003;181:1375-7.
8. Ono H, Kanematsu M, Kato H, Toyoki H, Hayasaki Y, Furui T, *et al.* MR imaging findings of uterine pyomyoma: Radiologic-pathologic correlation. *Abdom Imaging* 2014;39:797-801.
9. Peris H, del Riego J, Criado E, García-Chamón RB, Vall E, Mayoral M, *et al.* Value of diffusion-weighted magnetic resonance imaging in the diagnosis of pyomyoma. *Radiol Case Rep* 2021;17:137-41.
10. Magro M, Gafson I. Postpartum pyomyoma: A rare complication of leiomyoma. *J Obstet Gynaecol* 2014;34:202-3.

**How to cite this article:** Vincent G, Sudheer V, Varghese A, Joseph G. An intriguing case of acute abdomen secondary to ruptured pyomyoma: A case report. *Case Rep Clin Radiol*, doi: 10.25259/CRCR\_88\_2023