

## Case Series

# Acrorenal ocular syndrome: Case series of a rare familial congenital syndrome

Rajagopal Ganesh<sup>1</sup>, S. Shanmuga Jayanthan<sup>2</sup>, N. Karunakaran<sup>1</sup>, G. Rupesh<sup>2</sup>, K. Nadanasadharam<sup>2</sup>, Sidramappa Dande<sup>1</sup>

<sup>1</sup>Department of Radiology, Meenakshi Mission Hospital and Research Centre, Madurai, <sup>2</sup>Department of Radiology, Meenakshi Hospital, Thanjavur, Tamil Nadu, India.

### \*Corresponding author:

Rajagopal Ganesh,  
Department of Radiology,  
Meenakshi Mission Hospital  
and Research Centre, Madurai,  
Tamil Nadu, India.

radganesh1@yahoo.co.in

Received: 17 December 2022  
Accepted: 12 January 2023  
Epub Ahead of Print: 13 March 2023  
Published: 26 July 2023

DOI  
10.25259/CRCR\_50\_2022

Quick Response Code:



## ABSTRACT

Acrorenal ocular syndrome includes a spectrum of acral anomalies such as oligodactyly, ectrodactyly, syndactyly, brachydactyly, humerus/carpal hypoplasia, cutaneous syndactyly, and renal anomalies such as unilateral renal agenesis, unilateral hypoplasia, ectopia, horseshoe kidney, and vesico-ureteric reflex. The common ocular manifestations include Duane anomaly, coloboma, and ptosis.

**Keywords:** Renal anomaly, Acral anomaly, Familial syndrome

## INTRODUCTION

Acrorenal syndrome is a spectrum of congenital disorders characterized by the cooccurrence of distal limb anomalies and renal defects that can be associated with other anomalies such as those of genitourinary tract (genital anomalies, ureteral hypoplasias, and vesicoureteral reflux), abdominal wall defects, intestinal atresias, and lung malformations. Familial cases have been reported which may have either autosomal recessive or dominant inheritance.

## CASE SERIES

### Case 1

The propositus is a 25-years-old male, who presented with congenital acral anomalies decreased appetite since a month, easy fatigability since a month, and increasing pedal edema since a month.

He is born of a second-degree consanguineous marriage; term, normal vaginal delivery, cried normally after birth; there is no history of maternal diabetes/hypertension/abnormal drug intake. The developmental history is normal. He was apparently normal until the age of 19 years when he developed facial puffiness and bilateral pedal edema. These were gradually progressive but there was no history of decreased urine output, hematuria, fever, or recurrent UTI. Urine microscopy showed presence of albumin (+ + +), RBCs (6–8), and epithelial cells (1–2/hpf). Serum creatinine was 1.5 mg/dL, urea 35, BH 14.9, total count 13600, fasting glucose 112, serum cholesterol 221, and serum albumin 3.2 g.

This is an open-access article distributed under the terms of the Creative Commons Attribution-Non Commercial-Share Alike 4.0 License, which allows others to remix, transform, and build upon the work non-commercially, as long as the author is credited and the new creations are licensed under the identical terms.

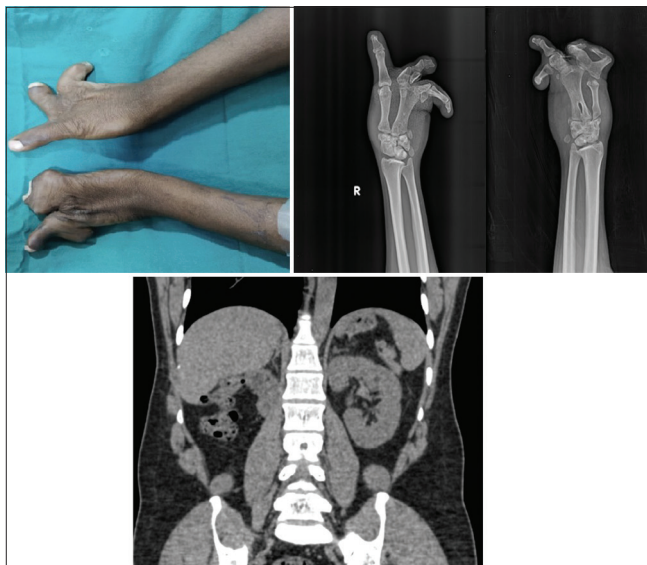
©2023 Published by Scientific Scholar on behalf of Case Reports in Clinical Radiology

The acral anomalies noted are oligodactyly, absent bilateral thumb, syndactyly and deformed, and fused carpal bones. Abdominal CT plain showed absent right kidney and normal position of the left kidney [Figure 1]. Further evaluation of the patient showed no cardiac abnormalities, no neurological abnormalities, no eye abnormalities, no spine abnormalities, and no lower limb deformities. CT brain plain and 2D echo were normal.

## Case 2

He is the younger brother of Case 1, 19-year-old, and had no presenting complaints. The patient was found to have acral anomalies at birth, which included bilateral hypoplastic thumbs, oligodactyly, syndactyly, and deformed/fused carpal bones. On imaging, the patient was found to have left cross fused ectopia [Figure 2]. Serum urea and creatinine were normal. However, he also did not have any eye abnormalities, no facial deformities, no lower limb deformities, no cardiac abnormalities, and no neurological abnormalities.

On further inquiry, we found that the patient's sister, who is younger to him also has acral abnormalities. Other than these three, three other people in the family, the propositus's father, paternal uncle and paternal aunt also had acral abnormalities, and all three have died. His father had two renal transplants and paternal uncle also had a renal transplant. Eye abnormalities could not be evaluated in other cases in the family except the propositus and his brother.



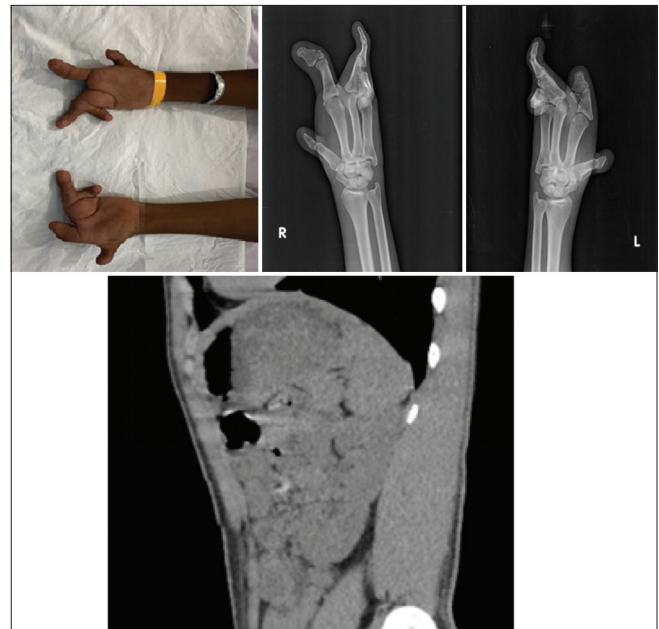
**Figure 1:** Clinical photograph and X-ray wrist joint AP show oligodactyly, absent bilateral thumb, syndactyly and deformed, and fused carpal bones in both hands. Coronal section of plain CT abdomen showing normal position of the left kidney and right renal agenesis.

## DISCUSSION

The incidence of renal and acral anomalies occurring together was first described by Dieter and Opitz in 1969.<sup>[2-4]</sup> The term acrorenal syndrome in such cooccurrences was first used by Curran and Curran in 1972.<sup>[3]</sup> The constellation of acral, renal, and eye anomalies represents a distinct autosomal dominant trait of variable expressivity in this syndrome.<sup>[4,5]</sup> Embryological fact is that development of all these organs is considered to be completed in the 6–8<sup>th</sup> week of embryogenesis.<sup>[6]</sup>

Difficulty in diagnosis often arise when not all features is present in an affected subject or within a family. The differential diagnosis of SALL4 (a gene product is a zinc finger protein which act as a transcription factor) related diseases includes Duane-radial ray syndrome (DRRS), (DRRS Okihiro syndrome), and SALL4-related Holt-Oram syndrome.<sup>[7]</sup> Other conditions such as Goldenhar syndrome, Wildervanck syndrome, Townes-Brocks syndrome, and Duane anomaly also possess certain constellation of findings similar to above SALL4-related diseases.<sup>[8]</sup>

Goldenhar syndrome differs from Okihiro syndrome and the acro-renal-ocular syndrome by the presence of hemifacial microsomia and epibulbar dermoid.<sup>[8]</sup> Goldenhar-like features including Duane anomaly can also be seen with Townes-Brocks syndrome. However, the later also feature renal anomaly, Sensorineural hearing loss, and thumb abnormalities.<sup>[8]</sup> In the acro-renal-ocular syndrome, renal abnormalities are frequent, but radial ray defects and/or ophthalmological findings may be



**Figure 2:** Clinical photograph and X-ray wrist joint AP show oligodactyly, absent bilateral thumb, syndactyly and deformed, and fused carpal bones in both hands. Sagittal section of plain CT abdomen showing cross-fused ectopia.

absent whereas, Wildervanck syndromes are characterized by the absence of limb abnormalities. Facial asymmetry and microtia have been reported frequently with Okihiro syndrome.<sup>[8]</sup>

The other syndromes that manifest with renal agenesis include Branchio-oto-renal syndrome (Melnick-Fraser syndrome), Renal coloboma syndrome (papillorenal syndrome), Alagille syndrome (arteriohepatic dysplasia), Winter syndrome, and CHARGE association.<sup>[1]</sup>

Branchio-oto-renal syndrome (Melnick-Fraser syndrome) is an autosomal dominant disease characterized by coexistence of deafness, branchial fistulae, pre-auricular pits, and renal anomalies, unilateral agenesis being more common.<sup>[1]</sup> Renal coloboma syndrome (papillorenal syndrome) is characterized by renal hypoplasia and agenesis, vesicoureteral reflux, and optic nerve coloboma. Almost all patients develop end-stage kidney disease.<sup>[8]</sup>

Alagille syndrome (arteriohepatic dysplasia) show marked arterionephrosclerosis with diffuse calcinosis, vertebral anomalies (butterfly vertebrae), peripheral pulmonary stenosis, mental and growth retardation, and neonatal cholestasis.<sup>[1]</sup> Winter syndrome is compiled by renal agenesis (unilateral/bilateral), middle-ear anomalies and internal genital malformations are noted in these patients.<sup>[1]</sup> CHARGE association includes duplicated upper pole of one kidney, coloboma, choanal atresia, cardiac, genital, and ear defects.<sup>[1]</sup>

## CONCLUSION

To conclude, SALL 4-related diseases are rare and one should be aware of all the syndromes. In our case due to no availability of genetic testing in our center, the patient was referred to a higher center for genetic/chromosomal testing and for further treatment. Counseling the patients against consanguineous marriage is important to prevent genetic inheritance of the disease.

DIFFERENTIAL DIAGNOSIS	DIFFERENTIATING FEATURES
1. Duane-radial ray syndrome also known as okihiro syndrome	<ul style="list-style-type: none"> <li>• Uni- or bilateral Duane anomaly</li> <li>• Radial ray malformations: thenar hypoplasia and/or hypoplasia or aplasia of the thumbs, hypoplasia or aplasia of the radii</li> <li>• Renal abnormalities may be present or absent</li> </ul>
2. Acro-renal ocular syndrome	<ul style="list-style-type: none"> <li>• Radial ray malformations</li> <li>• Renal abnormalities: mild malrotation, ectopia, horseshoe kidney, renal hypoplasia, vesicoureteral reflux, and bladder diverticula</li> <li>• Ocular abnormalities: Ocular coloboma and Duane anomaly</li> </ul>

DIFFERENTIAL DIAGNOSIS	DIFFERENTIATING FEATURES
3. SALL4-related Holt-Oram syndrome	<ul style="list-style-type: none"> <li>• Upper-extremity malformations</li> <li>• Congenital heart malformations: Ventricular septal defects, atrial septal defects, and tetralogy of Fallot</li> <li>• Cardiac conduction defects</li> <li>• Ear anomalies</li> </ul>
4. Goldenhar syndrome	<ul style="list-style-type: none"> <li>• Hemifacial macrosomia</li> <li>• Epibulbar dermoid</li> <li>• Klippel-Feil syndrome</li> <li>• Congenital ossicular anomalies</li> <li>• Duane syndrome</li> </ul>
5. Wildervanck syndrome	<ul style="list-style-type: none"> <li>• Absent limb abnormalities</li> <li>• Renal abnormalities</li> <li>• Anal abnormalities: anteriorly placed, stenotic, or imperforate anus</li> <li>• Ear anomalies- abnormally shaped pinna, external auditory canal stenosis, hearing loss.</li> <li>• Thumb abnormalities</li> </ul>
6. Townes-Brocks syndrome	<ul style="list-style-type: none"> <li>• Aberrant ocular movement due to absent or abnormal development of abducent nerve</li> <li>• Renal abnormalities: renal hypoplasia and agenesis</li> <li>• Optic nerve coloboma</li> <li>• Absent limb abnormalities</li> </ul>
7. Duane anomaly	<ul style="list-style-type: none"> <li>• Absent or abnormal development of abducent nerve</li> </ul>
8. Renal Coloboma syndrome	<ul style="list-style-type: none"> <li>• Renal abnormalities: renal hypoplasia and agenesis</li> <li>• Optic nerve coloboma</li> <li>• Absent limb abnormalities</li> </ul>

## TEACHING POINTS

1. It is important to be aware of these syndromes as they are very rare. It is also important to look for other abnormalities of a syndrome when suspected.
2. As they run in families of subsequent generation, genetic tree mapping to be done to assess the penetration and severity of the disease. It is also very important to create awareness about genetic counseling in consanguineous marriage.

## MCQ

1. All are SALL-4 associated syndromes except?
  - a) DRRS
  - b) Okihiro syndrome
  - c) Acro-renal-ocular syndrome
  - d) Renal coloboma

Answer Key: d

2. All are manifestations of acro-renal ocular syndrome except?
  - a) Oligodactyly
  - b) Renal agenesis
  - c) Ocular coloboma
  - d) Retinal detachment
  - e) Vesico-ureteric reflux

Answer: d

3. What is the mode of inheritance of SALL-4 associated syndromes?
  - a) Autosomal dominant

- b) Autosomal recessive
- c) X-linked recessive
- d) X-linked dominant

Answer: a

#### Declaration of patient consent

The authors certify that they have obtained appropriate patient consent.

#### Financial support and sponsorship

Nil.

#### Conflicts of interest

There are no conflicts of interest.

#### REFERENCES

1. Natarajan G, Jeyachandran D, Subramaniyan B, Thanigachalam D, Rajagopalan A. Congenital anomalies of kidney and hand: A review. *Clin Kidney J* 2013;6:144-9.
2. Halal F, Homsy M, Perreault G. Acro-renal-ocular syndrome: Autosomal dominant thumb hypoplasia, renal ectopia, and eye defect. *Am J Med Genet* 1984;17:753-62.

3. Curran AS, Curran JP. Associated acral and renal malformations: A new syndrome? *Pediatrics* 1972;49:716-25.
4. Dieker H, Opitz JM. Associated acral and renal malformations. *Birth Defects* 1969;5:68-77.
5. Siegler RL, Larsen P, Buehler BA. Upper limb anomalies and renal disease. *Clin Genet* 1980;17:117-9.
6. Naito T, Kida H, Yokoyama H, Abe T, Takeda S, Uno D, *et al.* Nature of renal involvement in the acro-renal-ocular syndrome. *Nephron* 1989;51:115-8.
7. Kohlhase J, Chitayat D, Kotzot D, Ceylaner S, Froster UG, Fuchs S, *et al.* SALL4 mutations in Okihiro syndrome (Duane-radial ray syndrome), acro-renal-ocular syndrome, and related disorders. *Hum Mutat* 2005;26:176-83.
8. Becker K, Beales PL, Calver DM, Matthijs G, Mohammed SN. Okihiro syndrome and acro-renal-ocular syndrome: Clinical overlap, expansion of the phenotype, and absence of PAX2 mutations in two new families. *J Med Genet* 2002;39:68-71.

**How to cite this article:** Ganesh R, Shanmuga Jayanthan S, Karunakaran N, Rupesh G, Nadasadharam K, Dande S. Acrorenal ocular syndrome: Case series of a rare familial congenital syndrome. *Case Rep Clin Radiol* 2023;1:61-4.