

## Case Report

# Aortic origin of the right pulmonary artery with patent ductus arteriosus: An infrequent encounter

Chetankumar Vajerambhai Dhandhalya<sup>1</sup>, Shilpa Chudasama<sup>1</sup>, Rutvik Champakbhai Patel<sup>1</sup> , Mihir Joshi<sup>1</sup>

<sup>1</sup>Department of Radiodiagnosis, Shri M.P. Shah Government Medical College, G. G. Government Hospital Campus, Jamnagar, Gujarat, India.

### \*Corresponding author:

Rutvik Champakbhai Patel,  
Department of Radiodiagnosis,  
Shri M.P. Shah Government  
Medical College, G.G.  
Government Hospital Campus,  
Jamnagar, Gujarat, India.

[drutvikpatel1@gmail.com](mailto:drutvikpatel1@gmail.com)

Received: 05 April 2023  
Accepted: 12 April 2023  
Epub Ahead of Print: 29 May 2023  
Published: 13 July 2024

### DOI

10.25259/CRCR\_55\_2023

### Quick Response Code:



## ABSTRACT

Aortic origin of the pulmonary artery (AOPA) is an infrequent congenital malformation. It is less frequently documented with an estimated prevalence of ~1%. Aortic origin of the right pulmonary artery is more common than the left. Frequent episodes of the lower respiratory tract infection and pulmonary arterial hypertension are common complications if left untreated. Despite causing significant morbidity diagnosis is delayed if AOPA is associated with patent ductus arteriosus (PDA). Our aim is to document a case of AOPA with PDA to explain the pathology, clinical implications, consequences, management options, and relevant literature review.

**Keywords:** Anomalous right pulmonary artery origin, Variants of right pulmonary artery, Patent ductus arteriosus, Pulmonary arterial hypertension, Aberrant pulmonary artery

## INTRODUCTION

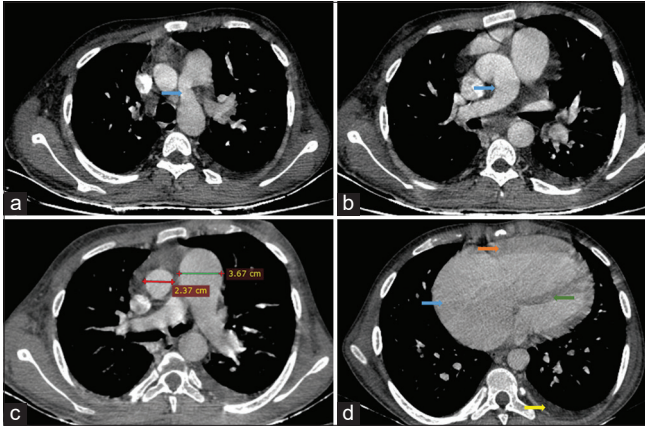
Pulmonary artery origin from the aorta is unusual and was first described by Fraentzel in 1868. The entire cardiac output from the right ventricle goes to one lung while the other lung receives blood at systemic pressure from the aorta resulting in a large left-to-right shunt. Other additional intracardiac shunting lesions often exacerbate the hemodynamic alterations. The pulmonary vasculature in bilateral lungs is at an increased risk of developing obstructive vascular disease. Early diagnosis is important since the lesion is amenable to surgical correction. Choosing the appropriate technique for repair depends on the site of origin of the anomalous pulmonary artery from the aorta.

## CASE REPORT

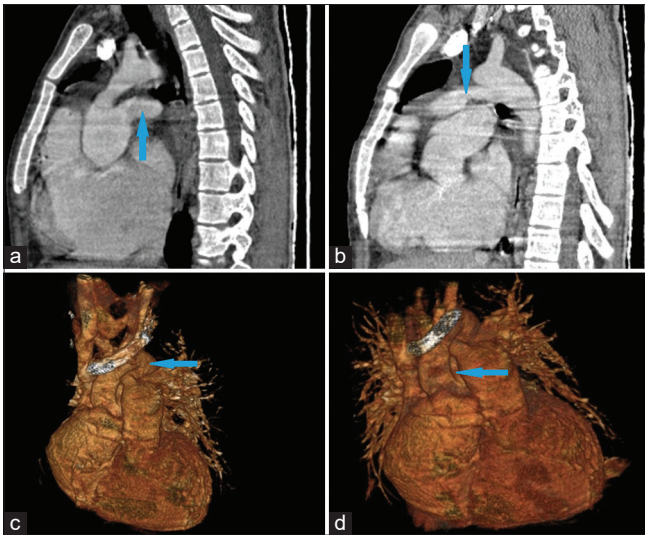
An 18-year-old Indian origin male born out of non-consanguineous marriage presented with complaints of recurrent episodes of expectorant cough and cold for 10 years associated with grade III Medical research council dyspnea. The patient was admitted once for the lower respiratory tract infection 4 years back. There was no evidence of cyanosis. Birth history was unremarkable with normal vaginal delivery and no neonatal intensive care unit stay. The patient presented with a fast breathing rate of 34/min and 82% oxygen saturation. His heart rate was 90/min and his blood pressure was 102/76 mmHg. On examination, there was grade 2 clubbing and mild respiratory distress, but the patient was conscious and oriented. All peripheral pulses were felt. Cardiac auscultation revealed a loud pulmonary component of S2 along with a continuous murmur heard at the left upper sternal border. ECG revealed normal sinus rhythm with p-wave peaking. Echocardiography indicated the absence of a typical pulmonary trunk bifurcation pattern with non-visualization of the right pulmonary artery. On basis of clinical and ECHO findings,

This is an open-access article distributed under the terms of the Creative Commons Attribution-Non Commercial-Share Alike 4.0 License, which allows others to remix, transform, and build upon the work non-commercially, as long as the author is credited and the new creations are licensed under the identical terms.

©2024 Published by Scientific Scholar on behalf of Case Reports in Clinical Radiology



**Figure 1:** (a) Computed tomography (CT) pulmonary angiography axial plane shows anomalous connection of size 1.3 cm between descending aorta and pulmonary trunk (blue arrow). (b) CT pulmonary angiography axial plane shows origin of the right pulmonary artery from ascending aorta (blue arrow). (c) CT pulmonary angiography axial plane shows changes of pulmonary hypertension in form of ascending aorta (23 mm) to main pulmonary artery (36 mm) ratio  $\ll 1$ . (d) CT pulmonary angiography axial plane shows right atrial dilatation (blue arrow), right ventricular hypertrophy (orange arrow), interventricular septal hypertrophy (green arrow), and left mild pleural effusion (yellow arrow).



**Figure 2:** (a) Computed tomography (CT) pulmonary angiography sagittal plane shows origin of the right pulmonary artery from ascending aorta (blue arrow). (b) CT pulmonary angiography sagittal plane shows anomalous connection of size 1.3 cm between descending aorta and pulmonary trunk (blue arrow). (c) CT pulmonary angiography 3D volume rendered image shows anomalous connection between descending aorta and pulmonary trunk (blue arrow). (d) CT pulmonary angiography 3D volume rendered image shows origin of the right pulmonary artery from ascending aorta (blue arrow).

contrast-enhanced computed tomography pulmonary angiography was advised. Multislice computed tomography (CT) pulmonary angiography showed the right pulmonary

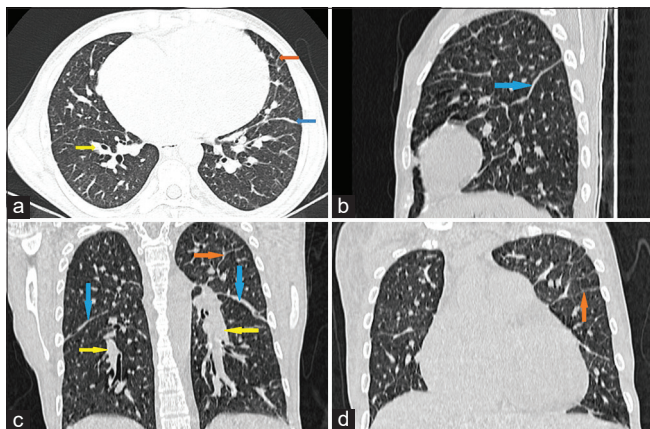
artery anomalously arising from ascending aorta along with (Krichenko Classification type III) patent ductus arteriosus (PDA) (1.3 cm) [Figures 1a and b]. There were changes of pulmonary artery hypertension in form of ascending aorta (23 mm) to main pulmonary artery (36 mm) ratio  $\ll 1$  [Figure 1c]. There was resultant severe right atrial dilatation, right ventricular and interventricular septal hypertrophy, moderate cardiomegaly, and left mild pleural effusion [Figure 1d]. CT pulmonary angiography sagittal reformats as well as 3D volume rendered images also confirmed the findings of right pulmonary artery anomalously arising from the ascending aorta along with patent ductus arteriosus. [Figure 2a-d]. Lung parenchyma showed significant smooth interlobular septal, peribronchovascular interstitial, and fissural thickening involving bilateral lung parenchyma, suggestive of interstitial pulmonary edema [Figure 3a-d].

## DISCUSSION

Aortic origin of the pulmonary artery (AOPA) is a rare cardiac anomaly among which aberrant origin of the right pulmonary artery is more common than the left pulmonary artery.<sup>[1]</sup> Left-sided AOPA is always associated with tetralogy of Fallot or aortic arch anomalies, whereas right-sided are usually associated with PDA like in our case.<sup>[2]</sup> Krichenko *et al.* divided PDA into five types: Type A – conical, Type B – window, Type C – Tubular, Type D – complex, and Type E – Elongated.<sup>[3]</sup> In our case, it was Type C. Incomplete migration of the right sixth aortic arch is stipulated theory for the right-sided proximal AOPA whereas for distal right AOPA absence or early regression of the distal right sixth aortic arch. For left-sided AOPA, improper fusion of the LPA to the MPA due to poor development of the left sixth arch is the proposed pathology.<sup>[4]</sup> There is high risk of developing pulmonary hypertension due to increased pulmonary tree blood flow, circulating vasoconstrictor substances, and neurogenic compounds flowing from the unprotected lung.<sup>[5]</sup>

CT pulmonary angiography is considered gold standard to diagnose anomalous vascular connections and our patient presented with complications of long-standing aortic origin of the right pulmonary artery. Pulmonary artery hypertension was indicated by  $\ll 1$  aortopulmonary ratio clinically presenting as dyspnea and decreased SPO<sub>2</sub> levels. Axial CT angiogram shows anomalous origin of the right pulmonary artery from the ascending aorta. The main pulmonary artery does not bifurcate but continues directly as the left pulmonary artery, displaying the moustache sign. The anomalous right pulmonary arterial origin associated with PDA and resultant changes of interstitial pulmonary edema and pulmonary arterial hypertension.

The early surgical intervention leads to a better prognosis. Direct implantation, end-to-end anastomosis with a synthetic graft, homograft patch, and “aortic-ring” flap are the methods used to reattach aberrant pulmonary artery to the main pulmonary trunk.<sup>[6]</sup> The patient was advised



**Figure 3:** (a-d) Computed tomography pulmonary angiography lung window axial plane significant smooth interlobular septal (orange arrows), peribronchovascular interstitial (yellow arrows), and fissural thickening (blue arrows) involving bilateral lung parenchyma.

to undergo right pulmonary artery implantation; however, consent was not given for surgery. At present, the patient is being treated symptomatically on follow-up basis.

## CONCLUSION

The right-sided AOPA is an infrequent encounter often associated with PDA and tetralogy of Fallot, thought to be a result of the failure of migration of the right sixth aortic arch. Early diagnosis and surgical intervention are the key to prevent complications such as pulmonary hypertension and recurrent lung infections.

## TEACHING POINTS

AOPA being a rare condition needs to be looked out for at earlier age before irreversible consequences occur. Surgical management at earlier age presents with a better prognosis.

## MCQs

- The most commonly associated anomaly with aortic origin of the right pulmonary artery is:
  - Patent ductus arteriosus
  - Ventricular septal defect
  - Interrupted aortic arch
  - Aberrant right subclavian artery

Answer Key: a

- Following characterize anomalous origin of the right pulmonary artery from ascending aorta:
  - Rare cardiac malformation accounting for 0.1% of all congenital heart defects.
  - Aortic origin of right pulmonary artery is 4–8 times more common than left pulmonary artery.
  - 85% is of proximal origin with 95% being detected in 1<sup>st</sup> year of life.

- All of the above.

Answer Key: d

- Thoracic imaging findings in case of aortic origin of the right pulmonary artery include:
  - Cardiomegaly
  - Large left to right cardiac shunt with changes of pulmonary edema-smooth interlobular septal thickening, peribronchovascular interstitial thickening, and pleural effusion.
  - Changes of pulmonary arterial hypertension-dilated pulmonary vessels, right ventricular wall hypertrophy, and interventricular septal hypertrophy.
  - All of the above.

Answer Key: d

## Ethical approval

Institutional Review Board approval is not required/waived-off.

## Declaration of patient consent

The authors certify that they have obtained all appropriate patient consent.

## Financial support and sponsorship

Nil.

## Conflicts of interest

There are no conflicts of interest.

## Use of artificial intelligence (AI)-assisted technology for manuscript preparation

The authors confirm that there was no use of artificial intelligence (AI)-assisted technology for assisting in the writing or editing of the manuscript and no images were manipulated using AI.

## REFERENCES

- Abu-Sulaiman RM, Hashmi A, McCrindle BW, Williams WG, Freedom RM. Anomalous origin of one pulmonary artery from the ascending aorta: 36 years' experience from one centre. *Cardiol Young* 1998;8:449-54.
- Truong QA, Massaro JM, Rogers IS, Mahabadi AA, Kriebel MF, Fox CS, *et al.* Reference values for normal pulmonary artery dimensions by noncontrast cardiac computed tomography: The Framingham Heart Study. *Circ Cardiovasc Imaging* 2012;5:147-54.
- Krichenko A, Benson LN, Burrows P, Mões CA, McLaughlin P, Freedom RM. Angiographic classification of the isolated, persistently patent ductus arteriosus and implications for percutaneous catheter occlusion. *Am J Cardiol* 1989;63:

- 877-80.
4. Hirsig LE, Sharma PG, Verma N, Rajderkar DA. Congenital pulmonary artery anomalies: A review and approach to classification. *J Clin Imaging Sci* 2018;8:29.
  5. Prifti E, Crucean A, Bonacchi M, Bernabei M, Leacche M, Murzi B, *et al.* Postoperative outcome in patients with anomalous origin of one pulmonary artery branch from the aorta. *Eur J Cardio Thorac Surg* 2003;24:21-7.
  6. Taksande A, Thomas E, Gautami V, Murthy K. Diagnosis of aortic origin of a pulmonary artery by echocardiography. *Images Paediatr Cardiol* 2010;12:5-9.

**How to cite this article:** Dhandhalya CV, Chudasama S, Patel RC, Joshi M. Aortic origin of the right pulmonary artery with patent ductus arteriosus: An infrequent encounter. *Case Rep Clin Radiol.* 2024;2:116-9. doi: 10.25259/CRCR\_55\_2023