

Case Report

A rare case of small bowel gangrene and perforation following high voltage electrical injury

Mallapu Vihar Reddy¹, Rajani Gorantla¹, Mallikarjuna Reddy Mandapati¹

¹Department of Radiology, NRI Medical College, Chinakakani, Andhra Pradesh, India.

*Corresponding author:

Mallapu Vihar Reddy,
Department of Radiology, NRI
Medical College, Chinakakani,
Andhra Pradesh, India.

mviharreddy@gmail.com

Received: 05 February 2023
Accepted: 23 May 2023
Epub Ahead of Print: 03 June 2023
Published: 26 July 2023

DOI
10.25259/CRCR_8_2023

Quick Response Code:



ABSTRACT

This case is a 42-year-old male with an alleged history of electric shock. About 8 h after the insult, an ulcer in the right iliac fossa increased in size with fecal matter coming out. Contrast-enhanced computed tomography of the abdomen revealed a full thickness anterior abdominal wall defect with prolapse of a segment of the distal ileal loop, showing discontinuous wall and no wall enhancement suggestive of evisceration and perforation of bowel with gangrene.

Keywords: Bowel gangrene, Electrical injury, Evisceration, Bowel perforation

INTRODUCTION

High-voltage electrical injuries are associated with severe consequences, typically presenting as burns and affecting the upper and lower limbs. However, abdominal wall defects and subsequent bowel evisceration are rare complications. We present a case of a 42-year-old male who suffered a high-voltage electrical injury while working on a high-tension electric pole, resulting in burns and subsequent development of bowel perforation and gangrene.

CASE REPORT

A 42-year-old male was brought to the emergency department 45 min after insult with an alleged history of electric shock while working on 11-kilovolt high-tension electric pole and fall from height. He sustained burns over bilateral upper limbs, anterior abdomen, and left thigh. On physical examination, there was an ulcer of size 1 × 0.5 cm present in the right iliac fossa with blackish discoloration of the surrounding skin [Figure 1a].

Initial radiological investigations done were ultrasound (USG) abdomen, computed tomography (CT) brain, and CT C-spine. There was no significant abnormality other than an undisplaced fracture of the left first rib. Even the USG abdomen showed no signs of any visceral injury. About 8 h after the insult, the ulcer in the right iliac fossa increased in size to around 4 × 3 cm with fecal staining [Figure 1b].

Contrast-enhanced CT (CECT) of the abdomen was done with plain, arterial and venous phases taken. It showed full thickness anterior abdominal wall defect in the right lower abdomen. A defect of size 2.5 × 2 cm (T × CC) was noted in the skin and subcutaneous planes. Defect of size 3.5 × 4.8 cm (T × CC) was noted in the right rectus abdominis muscle on the lateral

This is an open-access article distributed under the terms of the Creative Commons Attribution-Non Commercial-Share Alike 4.0 License, which allows others to remix, transform, and build upon the work non-commercially, as long as the author is credited and the new creations are licensed under the identical terms.

©2023 Published by Scientific Scholar on behalf of Case Reports in Clinical Radiology

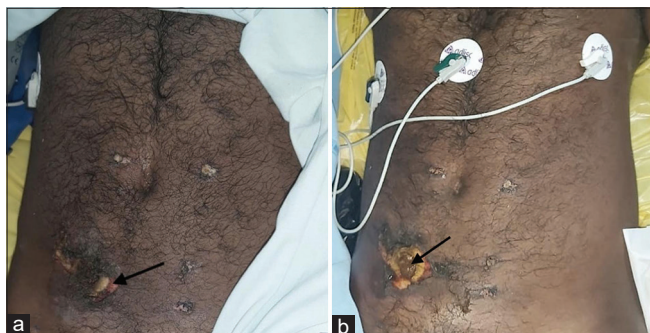

Figure 1: (a) About 45 min after insult, ulcer (black arrow) of size 1×0.5 cm seen in right iliac fossa with surrounding blackish discoloration. (b) About 8 h after the insult, the ulcer increased in size to around 4×3 cm with fecal matter coming out (black arrow).

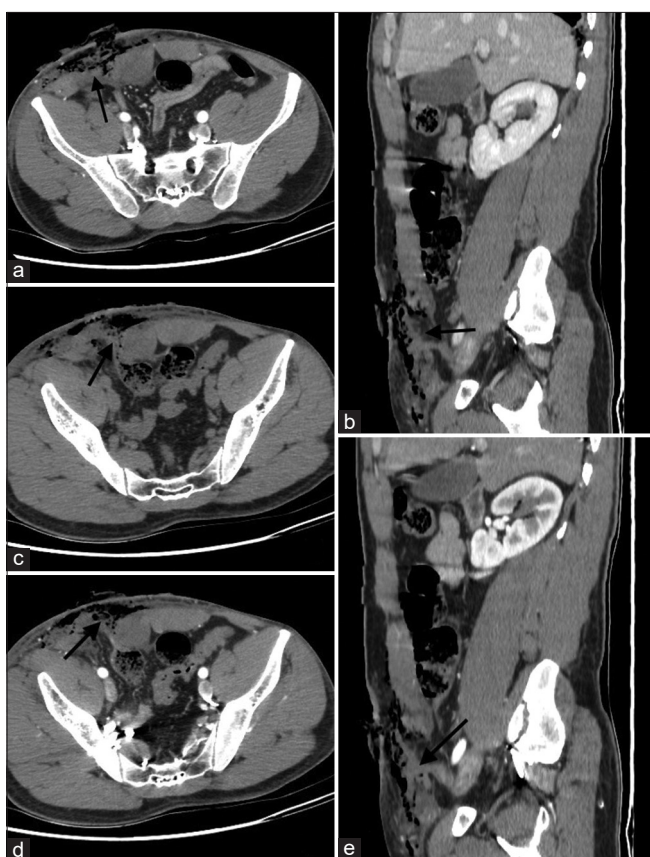

Figure 2: (a and b) Right rectus abdominis defect (black arrow) and defect in skin and subcutaneous tissue with mottled air foci and free fluid in subcutaneous plane seen on (a) Computed tomography (CT) arterial phase axial image (b) CT venous phase sagittal image. (c-e) Prolapse of a segment of the distal ileal loop through rectus defect showing discontinuous wall. (c) CT plain image (d) CT arterial phase axial and (e) sagittal images showing no wall enhancement suggestive of evisceration and perforation of bowel with gangrene.

aspect [Figure 2a and b]. Through the abdominal wall defect, there was prolapse of a segment of the distal ileal loop up

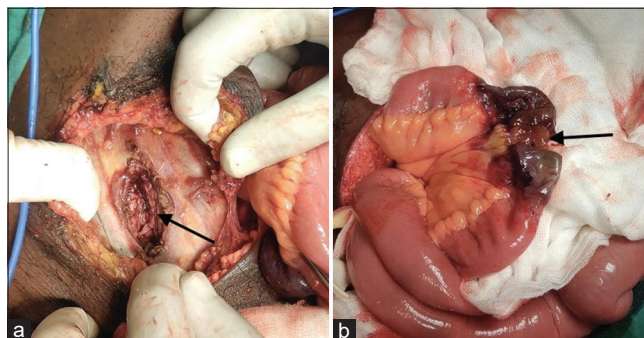


Figure 3: Intraoperative images (a) Perforated (black arrow) and gangrenous segment of the ileal loop. (b) Defect in rectus abdominis (black arrow).

to the subcutaneous plane showing discontinuous wall and no wall enhancement on contrast administration suggestive of evisceration and perforation of bowel with gangrene [Figure 2c-e]. Proximal to it, a few ileal loops were dilated with a maximum diameter measuring 2.8 cm, with mottled air and fecal matter and partial/non-enhancement of the mesenteric wall. Mottled air foci and free fluid were noted in the subcutaneous planes of the anterolateral abdominal wall on the right side. There was no obvious evidence of rupture or occlusion of superior mesenteric artery and vein or any of its visualized branches.

Emergency explorative laparotomy [Figure 3] with resection of gangrenous bowel segment and end-to-end anastomosis was done. Intra-operatively, 10 cm of the ileal loop has eviscerated which was gangrenous and perforated. A 2×1 cm necrotic patch was also detected about 10 cm distal to the gangrenous ileal loop. The gangrenous ileal loop along with the necrotic patch were resected and end-to-end anastomosis was done. Histopathological examination of resected bowel segment showed transmural ischemic necrosis consistent with gangrenous bowel. Debridement of the abdominal wound was done at a later date.

DISCUSSION

High-voltage electric current injuries (>1000 V, 50 Hz) are usually linked to workplace accidents when the worker is exposed to the energy source directly or indirectly through conductive materials or equipment.^[1] Electricity typically enters through the upper limbs and leaves through the lower limbs. Abdominal wall exits resulting in abdominal wall defect is uncommon and evisceration of bowel is far rarer.^[2]

Tissue injuries are caused by various mechanisms. The heat generated with the current passage causes denaturation of macromolecules which is usually irreversible.^[3] Exposure of cells to high voltage electricity increases membrane permeability through membrane electroporation which can

lead to necrosis.^[4] Current changes the orientation of polar amino acids in transmembrane proteins causing electro-conformational denaturation.^[5]

Tissues with high resistance cause greater heat production and greater injury.^[6] Large vessels have low resistance, hence usually spared. Small vessels, like those to bowel, have higher resistance causing coagulative necrosis of bowel.^[7]

In our case, fecal matter was found at the abdominal wound 8 h after the insult and the initial USG showed no signs of bowel perforation. Although delayed onset is typically defined as occurring after 48 h in most cases, in our report, we consider the occurrence of bowel perforation and gangrene within 8 h of the electrical insult as relatively delayed compared to immediate perforation. This timeframe may vary depending on individual cases and should be evaluated accordingly. Perforation in our case probably occurred due to irreversible local damage to small bowel, which might not be severe enough to cause instantaneous perforation. Gangrene in this case is likely attributed to a combination of factors, including ischemia resulting from the disruption of blood vessels and direct tissue damage caused by the high-voltage electrical injury. An initial CECT abdomen at the time of presentation might have revealed a non-enhancing segment of bowel. Hence, CECT abdomen could be done on a routine basis in cases of high voltage electrical injury.^[8]

CONCLUSION

This case report highlights the importance of considering visceral injuries in cases of high-voltage electrical injuries, even if initial evaluations appear normal. The occurrence of delayed bowel perforation and gangrene within a relatively short timeframe emphasizes the need for close monitoring and early intervention in such cases. Contrast-enhanced computed tomography (CECT) of the abdomen can aid in the diagnosis of visceral injuries and could be considered as a routine imaging modality in high-voltage electrical injuries.

TEACHING POINTS

1. In cases of high voltage electrical injuries, it is important to assess for signs of visceral injury, even if the initial examination and imaging studies appear to be normal.
2. Delayed bowel perforation may occur due to irreversible local damage to the bowel, which may not be severe enough to cause instantaneous perforation.
3. Contrast-enhanced computed tomography of the abdomen can be a useful diagnostic tool in cases of high voltage electrical injuries.

MCQs

1. What is the typical mode of entry and exit of electricity in high-voltage electrical injuries?

- a) Upper limbs to lower limbs
- b) Lower limbs to upper limbs
- c) Head to lower limbs
- d) Upper limbs to abdomen

Answer Key: a

2. Which of the following mechanisms of injury can be responsible for tissue damage in high voltage electrical injuries?
 - a) Electroporation induced necrosis
 - b) Heat induced denaturation of macromolecules
 - c) Electro-conformational denaturation
 - d) All the above

Answer Key: d

3. Why might bowel perforation be delayed in cases of high voltage electrical injuries?
 - a) Bowel perforation is not a common complication of high voltage electrical injuries.
 - b) Irreversible local damage to the bowel might not be severe enough to cause instantaneous perforation.
 - c) Bowel perforation usually occurs instantaneously and is not delayed.
 - d) High voltage electrical injuries usually cause reversible damage to the bowel.

Answer key: b

Declaration of patient consent

Patient's consent not required as patient's identity is not disclosed or compromised.

Financial support and sponsorship

Nil.

Conflicts of interest

There are no conflicts of interest.

REFERENCES

1. Marques EG, Júnior GA, Neto BF, Freitas RA, Yaegashi LB, Almeida CE, *et al.* Visceral injury in electrical shock trauma: proposed guideline for the management of abdominal electrocution and literature review. *Int J Burns Trauma* 2014;4:1-6.
2. Agrawal V, Jha A, Kumar K, Kalra G. Abdominal wall blow out causing bowel evisceration due to high voltage electrocution: A unique presentation. *Indian J Burns* 2015;23:88-91.
3. Tuttnauer A, Mordzynski SC, Wess YG. Electrical and lightning injuries. *Contemp Crit Care* 2006;7:1-10.
4. Napotnik TB, Polajžer T, Miklavčič D. Cell death due to electroporation - A review. *Bioelectrochemistry* 2021;141:107871.
5. Chen W. Electroconformational denaturation of membrane proteins. *Ann N Y Acad Sci* 2005;1066:92-105.
6. Faes TJ, van der Meij HA, de Munck JC, Heethaar RM. The

electric resistivity of human tissues (100 Hz-10 MHz): A meta-analysis of review studies. *Physiol Meas* 1999 20:R1-10.

7. Kumar S, Thomas S, Lehri S. Abdominal wall and stomach perforation following accidental electrocution with high tension wire: A unique case. *J Emerg Med* 1993;11:141-5.
8. Goyal D, Dhiman A, Jagne N, Rattan A. Delayed bowel

perforation in electrocution: An unpredictable foe. *Trauma Case Rep* 2020;30:100377.

How to cite this article: Reddy MV, Gorantla R, Mandapati MR. A rare case of small bowel gangrene and perforation following high voltage electrical injury. *Case Rep Clin Radiol* 2023;1:140-3.