

Case Report

Acrocallosal syndrome: Classical findings in a case report with a literature review

Siddhi Chawla¹, Aditya Charan¹

¹Department of Radiology, Sardar Patel Medical College, Bikaner, Rajasthan, India.

*Corresponding author:

Siddhi Chawla,
Department of Radiology,
Sardar Patel Medical College,
Bikaner, Rajasthan, India.

siddhi.chawla870@gmail.com

Received: 26 August 2023
Accepted: 11 September 2023
Epub Ahead of Print: 07 December 2023
Published:

DOI
[10.25259/CRCR_143_2023](https://doi.org/10.25259/CRCR_143_2023)

Quick Response Code:



ABSTRACT

We present a case of a 1-day-old neonate with classical findings of acrocallosal syndrome. The child presented with difficulty in feeding. Clinically, the patient had craniofacial anomalies and digital malformations. Imaging with ultrasonography and magnetic resonance imaging revealed characteristic features of corpus callosum agenesis with dandy walker malformation. A classical case of acrocallosal syndrome with sporadic occurrence is discussed with a detailed review of all such previously reported cases in the literature till date and a discussion of possible differentials.

Keywords: Acrocallosal syndrome, Agenesis of corpus callosum, Polydactyly, Magnetic resonance imaging, Pediatric radiology

INTRODUCTION

Acrocallosal syndrome (ACS) was first described by Schinzel in 1979,^[1] as a conundrum of findings, including post-axial polydactyly, duplication of the hallux, and abnormality of corpus callosum including agenesis or dysgenesis, occasional anencephaly, and/or Dandy-Walker malformation, characteristic craniofacial abnormalities, and moderate-to-severe mental retardation. In clinical practice, however, the clinical, physical, and imaging findings vary over a spectrum and hence vary with the age of presentation. The inheritance pattern of ACS is autosomal recessive with the gene situated on chromosome 12p caused due to mutations in the KIF7 gene;^[2,3] however, sporadic cases have also been reported.^[4] Our case describes the classical findings in ACS in a 1-day-old neonate which is the second case presented at this age according to the reported literature.^[4]

CASE PRESENTATION

A 1-day-old full-term male child delivered vaginally as a result of non-consanguineous marriage presented to the pediatric outpatient department (OPD) with a history of inability to suck and respiratory difficulty. He was the first-born child for the parents and no history of abortions was there. No antenatal scans were performed for the mother; however, the delivery was performed in a primary health center. The baby did not cry at birth and hence was referred to our hospital for management. The birth weight of the child was 2.7 kg (15–50th centile) and had a head circumference of 36 cm (85th centile). On physical examination, the baby had hypertelorlic eyes

This is an open-access article distributed under the terms of the Creative Commons Attribution-Non Commercial-Share Alike 4.0 License, which allows others to remix, transform, and build upon the work non-commercially, as long as the author is credited and the new creations are licensed under the identical terms.

©2023 Published by Scientific Scholar on behalf of Case Reports in Clinical Radiology

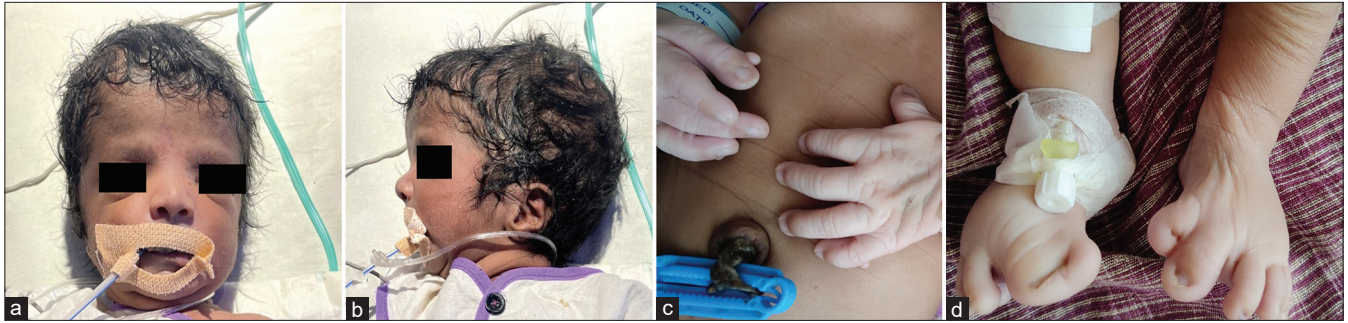

Figure 1: Photographs of patient show (a) hypertelorism and flat nasal bridge, (b) lateral profile shows low set ears, (c) hands show post-axial polydactyly in right hand and pre-axial polydactyly in left hand, and, (d) polysyndactyly in the right hallux and post axial polydactyly in left foot.

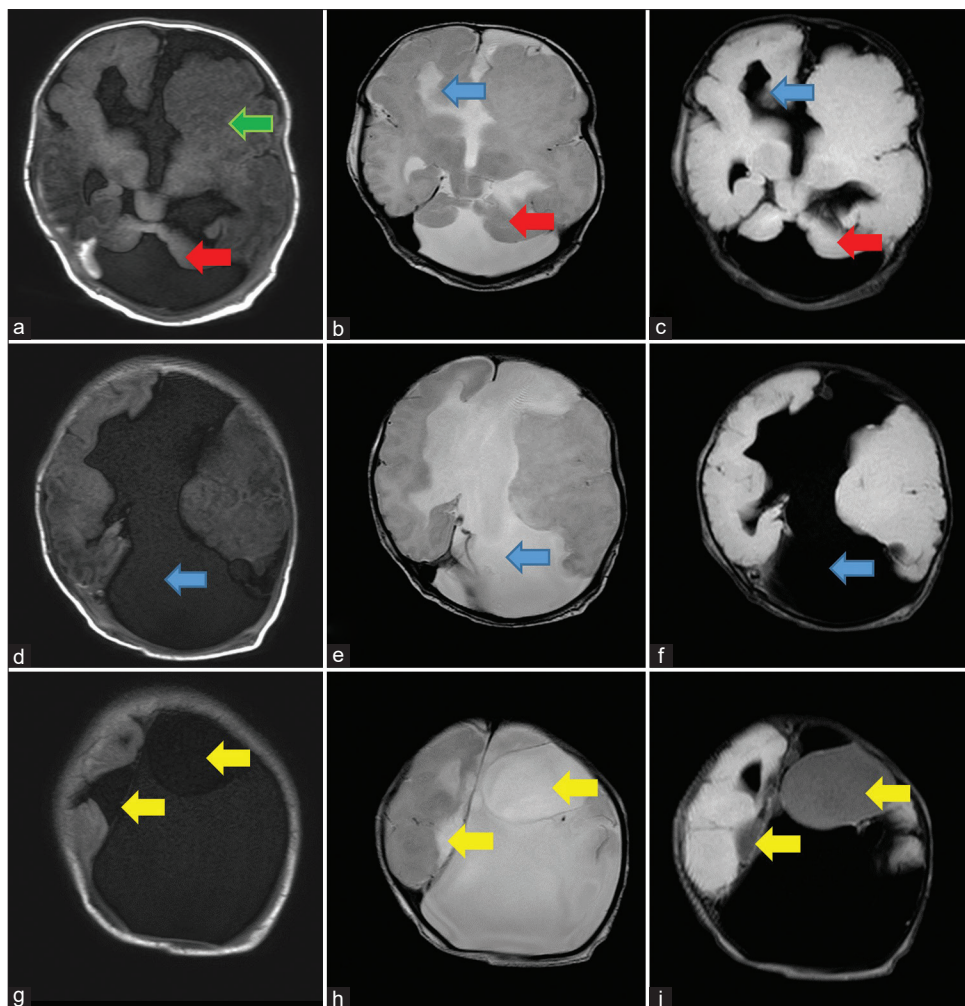


Figure 2: Sequential axial sections of MRI shows: First row: (a) T1 weighted image shows dysmorphic left cerebral hemisphere with polymicrogyria (green arrow), bilateral cerebellar hypoplasia with a large posterior fossa cyst (red arrow), (b), T2 and (c) FLAIR weighted image, shows widely placed right frontal horn of lateral ventricle (blue arrows) and bilateral cerebellar hypoplasia with large posterior fossa cyst (red arrows), Second row: (d) T1 weighted image, (e) T2 weighted image and (f) FLAIR weighted images show non visualization of corpus callosum with large CSF intensity inter-hemispheric cyst (blue arrows seen in d-f), and Third row: (g) T1 weighted image, (h) T2 weighted image and (i) FLAIR weighted images shows few cysts which are not suppressing on FLAIR (yellow arrows seen in g-i).

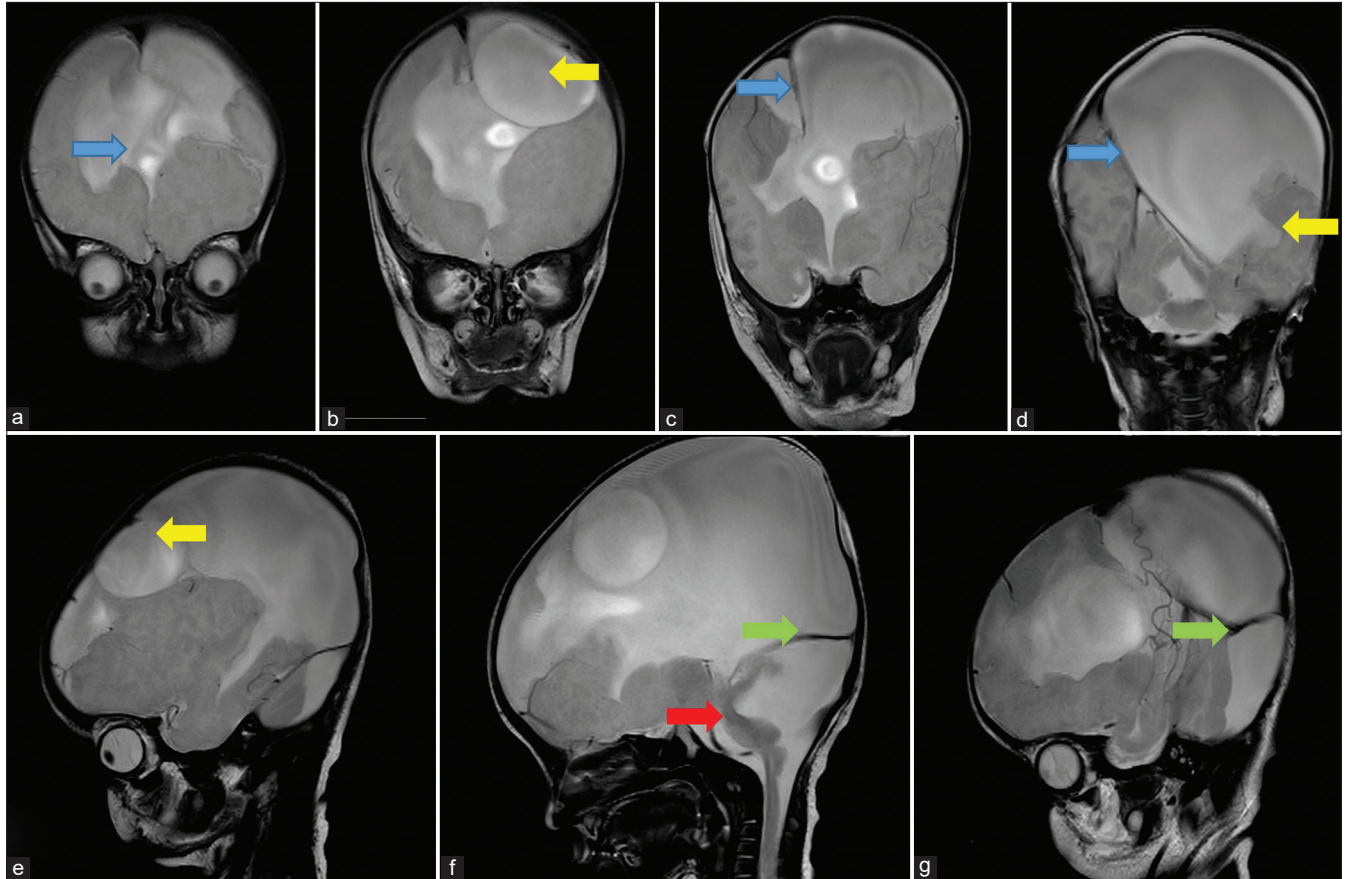


Figure 3: Sequential coronal (a-d) and Sagittal (e-g) T2 weighted MRI images shows: (a) absence of anterior falx cerebri (blue arrow), (b) inter-hemispheric cyst (yellow arrow), (c) presence of falx cerebri in posterior aspect (blue arrow), (d) inter-hemispheric cyst communicating with lateral ventricle (yellow arrow) and presence of falx cerebri further posteriorly (blue arrow), (e) inter-hemispheric cyst (yellow arrow), (f) cerebellar hypoplasia with large posterior fossa cyst (red arrow) causing torcular inversion (green arrow) and, (g) High tentorium cerebelli signifying torcular inversion (green arrow).

with frontal bossing, a flat nasal bridge, and low-set ears [Figure 1]. There was pre-axial polydactyly in the left hand and post-axial polydactyly in the right hand, and both feet as well as duplication in both hallux with fusion of the right hallux [Figure 1]. Neurological examination showed mild hypotonia with sluggish reflexes. No history of abnormal body movements was present. Cardiovascular examination showed tachycardia with ejection systolic murmur. Abdominal and genitourinary examination was normal. Echocardiography revealed a patent foramen ovale with the normal position of the heart. Magnetic resonance imaging (MRI) brain revealed complete corpus callosum agenesis with large interhemispheric cysts not suppressed on fluid-attenuated inversion recovery sequences [Figure 2]. There was non-visualization of anterior falx with associated dysplasia of the left cerebral hemisphere with non-visualization of the frontal horn of the left lateral ventricle and atria of ventricle opening into a large cerebrospinal fluid intensity cyst in the interhemispheric region [Figure 3]. There was also associated bilateral cerebellar and vermal hypoplasia with a large

posterior fossa cyst and torcular inversion consistent with Dandy–Walker malformation [Figures 2 and 3]. Ultrasound of the abdomen and pelvis was normal. Septic screen and metabolic profile were normal. The whole exome sequencing report revealed no particular gene mutation in our patient including the specific emphasis on the KIF7 gene. Parents were counseled regarding the sporadic nature of the disease in their child and the possible autosomal recessive nature of inheritance and were advised insertion of a cyst-peritoneal shunt by a neurosurgical team; however, they refused any surgical intervention and opted for treatment with home care and alternative sources of medicine. The patient since then was lost to follow-up.

DISCUSSION

ACS is rare with only a limited number of cases being described in the literature. To the best of our knowledge, this is the fifth reported case in the Indian population.^[4,5] Most of the cases have reported an autosomal recessive

Table 1: Features of the acrocallosal syndrome and spectrum in cases reported according to the updated literature (PUBMED till July 2022).

No.	Features	Authors	Our case
Clinical manifestations			
1.	Macrocephaly	Bhambal <i>et al.</i> (2015), ^[5] Subramanian <i>et al.</i> (2019), ^[7] Revanna <i>et al.</i> (2018), ^[9] Ibisler <i>et al.</i> (2015), ^[10] Schinzel and Schmid (1980) ^[11]	+
2.	Seizures/abnormal EEG	Revanna <i>et al.</i> (2018), ^[9] Schinzel <i>et al.</i> (1986), ^[12] Koenig <i>et al.</i> (2002) ^[13]	-
3.	Hypotonia	Bhambal <i>et al.</i> (2015), ^[7] Yuksel <i>et al.</i> (1990), ^[14]	+
4.	Hypertelorism and frontal bossing	Bhambal <i>et al.</i> (2015), ^[5] Subramanian <i>et al.</i> (2019), ^[7] Ibisler <i>et al.</i> (2015), ^[10] Schinzel (1988), ^[15] Hosdurg <i>et al.</i> (2018), ^[16]	+
Neurological manifestations			
5.	Agenesis/hypoplasia of corpus callosum	Bhambal <i>et al.</i> (2015), ^[5] Lamrissi <i>et al.</i> (2022), ^[6] Subramanian <i>et al.</i> (2019), ^[7] Revanna <i>et al.</i> (2018), ^[9] Ibisler <i>et al.</i> (2015), ^[10] Hosdurg <i>et al.</i> (2018), ^[16] Moeachler <i>et al.</i> (1987) ^[17]	+
6.	Cerebellar hypoplasia (including dandy walker malformation)	Ibisler <i>et al.</i> (2015), ^[10] Hosdurg <i>et al.</i> (2018), ^[16] Hendrik <i>et al.</i> (1990) ^[18]	+
7.	Brainstem dysplasia, joubert syndrome, hippocampal malrotation	Subramanian <i>et al.</i> (2019) ^[7]	-
8.	Optic atrophy	Hendriks <i>et al.</i> (1990) ^[18]	-
9.	Olfactory bulb agenesis and olfactory tract abnormalities	Subramanian <i>et al.</i> (2019), ^[7]	-
Musculoskeletal manifestations			
10.	Hallux duplication	Ibisler <i>et al.</i> (2015), ^[10] Schinzel and Schmid (1980), ^[11] Hosdurg <i>et al.</i> (2018) ^[16]	+
11.	Pre- and post-axial polydactyly of toes and fingers	Revanna <i>et al.</i> (2018), ^[9] Ibisler <i>et al.</i> (2015), ^[10] Schinzel (1988), ^[15] Hendriks <i>et al.</i> (1990) ^[18]	+
12.	Cranial synostosis	Subramanian <i>et al.</i> (2019) ^[7]	-
13.	Orofacial malformations	Bhambal <i>et al.</i> (2015), ^[5] Lamrissi <i>et al.</i> (2022), ^[6] Hosdurg <i>et al.</i> (2018) ^[16]	-
14.	Rib anomalies	Singhal <i>et al.</i> (2014) ^[4]	-
15.	CTEV	Hosdurg <i>et al.</i> (2018) ^[16]	-
Cardiac manifestations			
16.	Congenital heart disease	Ibisler <i>et al.</i> (2015), ^[10] Hosdurg <i>et al.</i> (2018), ^[16] Casamassima <i>et al.</i> (1989) ^[19]	+
17.	Dextro position of the heart	Singhal <i>et al.</i> (2014) ^[4]	-
18.	Cyanotic spells	Yuksel <i>et al.</i> (1990) ^[14]	-
Others			
19.	Delayed fall of cord	Singhal <i>et al.</i> (2014) ^[4]	+

CTEV: Congenital talipes equinus varus, EEG: Electroencephalogram

inheritance and a history of consanguineous marriage.^[6] Recent studies have shown mutations in the genes of kinesin KIF and transcription factor Gli3 which are involved in the ciliary signaling pathway involving the sonic hedgehog which is responsible for the formation of midline structures;^[7] however, our case did not reveal any mutation in these genes, opening the possibility of an unknown gene mutation or sporadic occurrence. The disruptions in the development of the corpus callosum occur during the 5th-16th week of pregnancy.^[5] Courtens *et al.* have given the diagnostic criteria for ACS as the presence of any three out of the four features, which include: (1) absence/hypoplasia/dysgenesis of the corpus callosum, (2) craniofacial dysmorphism, (3) polysyndactyly, and (4) psychomotor retardation.^[8] Our case fulfilled all the given criteria in addition to having dandy walker malformation and cardiac involvement in the form of patent foramen ovale. With the increase in the number of cases being reported, there is a definite phenotypic variation as shown

in [Table 1]. A variety of other syndromes are associated with agenesis of corpus callosum as well as polysyndactyly and due to overlap of phenotype, a differentiation of ACS from these syndromes is essential. [Table 2] summarizes the salient clinical features of these syndromes along with the differentiating features which help us to make a definite diagnosis of ACS. The prognosis of ACS depends on the degree of hypotonia and age of onset of seizures in addition to the associated malformations.^[6] Life span of patients range from stillbirth to relatively normal lives with variable degrees of developmental delay.^[5] A periodic follow-up of the patient with a pediatric neurologist, cardiologist, otolaryngologist, speech therapist, and child psychologist is recommended to the parents. Since there is a 25% chance of recurrence of this syndrome in the next child, genetic counseling of the parents is given utmost importance in detected cases.^[5,6] Central nervous system malformations and polysyndactyly can be readily detected on antenatal scan and hence a judicious imaging follow-up

Table 2: Syndromes associated with corpus callosum agenesis and polysyndactyly and their differentiating features from acrocallosal syndrome.

	Classical features	Differentiating features
Syndromes associated with corpus callosum agenesis		
Aicardi syndrome	Infantile spasms, chorioretinal lacunae, microcephaly, polymicrogyria, porencephalic cysts; enlarged cerebral ventricles due to hydrocephalus	No association of polysyndactyly; Absence of seizures
Andermann syndrome	Motor and sensory neuropathy, mild mental retardation, mild facial dysmorphism (including hypertelorism, short nose, broad nasal root, high arched palate, elongated facies, and ptosis)	No association of polysyndactyly, Absence of neuropathy
Shapiro syndrome	Paroxysmal hypothermia, hyperhidrosis	Absence of clinical features, absence of polysyndactyly
DiGeorge syndrome	Congenital heart disease, defects in the palate, neuromuscular problems, learning disabilities, mild differences in facial features, and recurrent infections	Absence of polysyndactyly, absence of hypotonia
Syndromes associated with polysyndactyly		
Greig cephalopolysyndactyly syndrome	Hypertelorism, macrocephaly, frontal bossing, and polysyndactyly	Absence of central nervous system anomalies
Oro-facial-digital syndrome type II	Hypertelorism, polysyndactyly, cleft lip and palate, conductive deafness, choroidal coloboma, renal and cardiac defects	Absence of hypotonia, Absence of central nervous system anomalies, and Absence of clinical features
Smith-Lemli-Opitz syndrome (7-dehydroxycholesterol reductase deficiency)	Psychomotor retardation, microcephaly, hypotonia, holoprosencephaly, low-set ears, micrognathia, polysyndactyly, cardiac anomalies, and urogenital anomaly	Absence of classical corpus callosum anomalies, Absence of macrocephaly
Rubenstein Taybi syndrome	Facial dysmorphism, limb anomalies, microcephaly, intellectual retardation, congenital cardiac abnormalities, and hirsutism	Absence of classical corpus callosum anomalies, Absence of macrocephaly, and absence of psychomotor retardation

in all future pregnancies is advised for mothers detected with ACS in one offspring.

CONCLUSION

ACS is a rare anomaly and only a few cases have been reported in the Indian population. Imaging plays an important role in antenatal diagnosis of this condition. Postnatally, imaging is essential for the diagnosis of corpus callosum agenesis along with other associated cranial, facial, and digital anomalies that distinguish it from other syndromes. Early recognition of the condition is necessary to intervene surgically and to counsel the parents regarding the genetics of the disease and dedicated follow-up of the affected child in special OPDs. Molecular testing should be done in all suspected cases.

TEACHING POINTS

1. ACS is rare and a conundrum of clinical features such as facial and digital anomalies (polydactyly)

should prompt the clinician to perform a radiological investigation with an MRI brain to look for corpus callosum anomalies.

2. Genetic testing is suggested for all cases with suspected ACS to look for the KIF7 gene and yet unknown mutations that can present with similar morphology.

MCQs

1. Which of the following clinical features is not a criterion to diagnose acrocallosal syndrome?
 - a. Psychomotor retardation
 - b. Polydactyly
 - c. Seizures
 - d. Craniofacial dysmorphism

Answer Key: c

2. Which are the essential MRI findings to diagnose acrocallosal syndrome?
 - a. Corpus callosum dysgenesis
 - b. Dandy walker malformation

- c. Schizencephaly
- d. Hydrocephalus

Answer Key: a

3. Which of the following is not associated with microcephaly?
- a. Aicardi syndrome
 - b. Acrocallosal syndrome
 - c. TORCH infection
 - d. Apert syndrome

Answer Key: b

Ethical approval

The research was in compliance with Helsinki declaration 1964.

Declaration of patient consent

The authors certify that they have obtained all appropriate patient consent.

Financial support and sponsorship

Nil.

Conflicts of interest

There are no conflicts of interest.

Use of artificial intelligence (AI)-assisted technology for manuscript preparation

The authors confirm that there was no use of artificial intelligence (AI)-assisted technology for assisting in the writing or editing of the manuscript and no images were manipulated using AI.

REFERENCES

1. Schinzel A. Postaxial polydactyly, hallux duplication, absence of the corpus callosum, macrencephaly and severe mental retardation: A new syndrome? *Helv Paediatr Acta* 1979;34:141-6.
2. Pfeiffer RA, Legat G, Trautmann U. Acrocallosal syndrome in a child with de novo inverted tandem duplication of 12p11.2-p13.3. *Ann Genet* 1992;35:41-6.
3. Putoux A, Thomas S, Coene KL, Davis EE, Alanay Y, Ogur G, *et al.* KIF7 mutations cause fetal hydrolethals and acrocallosal syndromes. *Nat Genet* 2011;43:601-6.
4. Singhal R, Pandit S, Saini A, Singh P, Dhawan N. The

acrocallosal syndrome in a neonate with further widening of phenotypic expression. *Iran J Child Neurol* 2014;8:60-4.

5. Bhambal AM, Bhambal A, Nair P, Bhambal SS. Orofacial manifestations in cases with partial agenesis of corpus callosum-rare phenomena. *J Oral Biol Craniofac Res* 2015;5:106-11.
6. Lamrissi A, Madri FE, Charkaoui M, Mourabbih M, Jalal M, Bouhya S. Acro-callous syndrome: A case report. *Int J Surg Case Rep* 2022;96:107210.
7. Subramanian S, Soundara Rajan D, Gaesser J, Wen-Ya Lo C, Panigrahy A. Olfactory bulb and olfactory tract abnormalities in acrocallosal syndrome and Greig cephalopolysyndactyly syndrome. *Pediatr Radiol* 2019;49:1368-73.
8. Courtens W, Vamos E, Christophe C, Schinzel A. Acrocallosal syndrome in an Algerian boy born to consanguineous parents: Review of the literature and further delineation of the syndrome. *Am J Med Genet* 1997;69:17-22.
9. Revanna KG, Rajadurai VS, Chandran S. Agenesis of the corpus callosum with interhemispheric cyst: Clinical implications and outcome. *BMJ Case Rep* 2018;11:bcr2018227366.
10. Ibsler A, Hehr U, Barth A, Koch M, Epplen JT, Hoffjan S. Novel KIF7 mutation in a Tunisian boy with acrocallosal syndrome: Case report and review of the literature. *Mol Syndromol* 2015;6:173-80.
11. Schinzel A, Schmid W. Hallux duplication, postaxial Polydactyly, absence of corpus callosum, severe mental retardation and additional anomalies in two unrelated patients: A new syndrome. *Am J Med Genet* 1980;6:241-9.
12. Schinzel A, Kaufmann U. The acrocallosal syndrome in sisters. *Clin Genet* 1986;30:399-405.
13. Koenig R, Bach A, Woelki U, Grzeschik KH, Fusch S. Spectrum of acrocallosal syndrome. *Am J Med Genet* 2002;108:7-11.
14. Yuksel M, Caliskan M, Ogur G, Ozmen M, Dolunary G, Apak S. The acrocallosal syndrome in a Turkish Boy. *J Med Genet* 1990;27:48-9.
15. Schinzel A. The acrocallosal syndrome in first cousins: Widening of the spectrum of clinical features and further support for autosomal inheritance. *J Med Genet* 1988;25:332-6.
16. Hosdurg B, Nair AP, Simha J, Sriramanan S. Anaesthetising an infant with acrocallosal syndrome: An unusual case. *Indian J Anaesth* 2018;62:389-91.
17. Moeschler JB, Pober BR, Holmes LB, Graham JM Jr. Acrocallosal syndrome: New findings. *Am J Med Genet* 1989;32:195-199.
18. Hendriks HJE, Brunner HG, Haagen TAM, Hamel BCJ. Acrocallosal syndrome. *Am J Med Genet* 1990;35:443-6.
19. Casamassima AC, Beneck D, Gewitz MH, Horowitz MA, Woolf PK, Pettersen IM, *et al.* Acrocallosal Syndrome: Additional manifestation. *Am J Med Genet* 1989;32:311-7.

How to cite this article: Chawla S, Charan A. Acrocallosal syndrome: Classical findings in a case report with a literature review. *Case Rep Clin Radiol*. doi: 10.25259/CRCR_143_2023