

Case Report

Meckel's diverticulitis: A frequently overlooked mimic of appendicitis

Khushboo Tekriwal¹, Anjali Anant Bhoir¹, H. S. Karthik¹

¹Department of Radiology, Seth GS Medical College and KEM Hospital, Mumbai, Maharashtra, India.

*Corresponding author:

Khushboo Tekriwal,
Department of Radiology,
Seth GS Medical College
and KEM Hospital, Mumbai,
Maharashtra, India.

khushbootekriwal300995@
gmail.com

Received: 22 March 2023
Accepted: 06 April 2023
Epub Ahead of Print: 09 May 2023
Published: 13 July 2024

DOI
10.25259/CRCR_43_2023

Quick Response Code:



ABSTRACT

Although Meckel's diverticulum is the most prevalent congenital abnormality of the gastrointestinal tract, it is often misdiagnosed due to its varied and overlapping clinical presentation, mimicking other common disorders such as appendicitis, Crohn's disease, and peptic ulcer disease. It may remain completely asymptomatic. Ultrasonograms and computed tomography together can direct the treating surgeons toward diagnosis and planning appropriate surgery by reducing the complications of emergency laparotomy. Other more advanced imaging modalities, such as scintigraphy and invasive angiography, can be reserved for inconclusive cases. Knowing the imaging features of Meckel's diverticulitis on ultrasonogram will decrease the mortality and morbidity related to misdiagnosed or undiagnosed cases of Meckel's diverticulum, especially among patients in 2-tier or 3-tier cities as ultrasonography centers nowadays are readily available in remote areas.

Keywords: Meckel's diverticulitis, Mesodiverticular band, Omphalomesenteric duct, Ultrasonogram in Meckel's, Umbilical or periumbilical cyst

INTRODUCTION

Meckel's diverticulum is a true congenital small intestinal diverticulum present in approximately two per cent of the population. In most cases, it remains silent throughout life. It has varied presentations which overlap with common conditions such as acute appendicitis. As the incidence of acute appendicitis significantly outweighs Meckel's diverticulitis, it is often overlooked. This is a case of a 15-year-old boy who presented with signs and symptoms of acute appendicitis, later confirmed to be a perforated inflamed Meckel's diverticulum.

CASE REPORT

A 15-year-old boy presented to the surgical emergency with acute pain in the periumbilical region for 1 day. On clinical examination, tenderness was elicited on superficial and deep palpation, predominantly in the right iliac fossa (RIF). A lump was felt in the right periumbilical region. A clinical diagnosis of appendicular perforation with an appendicular chunk was made. His complete blood hemogram was normal, with a total leukocyte count of 10,000/mm³. Electrolytes, liver function tests, urinalysis, and amylase levels were within normal limits. The upright abdominal radiograph was normal. He underwent an emergency ultrasonogram which showed a blind-ending bowel loop ending into a small bowel loop in the RIF with a collection at the apex and suspicious sealed perforation in its posterior wall [Figure 1a]. This loop was directed towards the midline, and a fibrous band was seen connecting its tip

This is an open-access article distributed under the terms of the Creative Commons Attribution-Non Commercial-Share Alike 4.0 License, which allows others to remix, transform, and build upon the work non-commercially, as long as the author is credited and the new creations are licensed under the identical terms.

©2024 Published by Scientific Scholar on behalf of Case Reports in Clinical Radiology

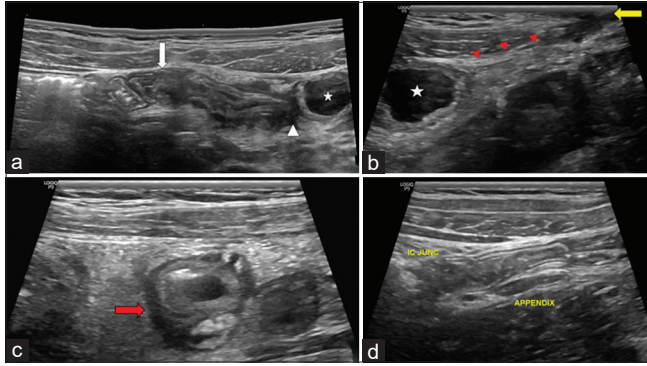


Figure 1: Sonogram of the lower abdomen of a 15-year-old boy using a linear high-frequency transducer show (a) A 4.5 cm long, blind-ending bowel loop arising from the ileum (white arrow) with a fluid-filled collection showing gut signature at its apex (white asterisk). Its posterior wall near the apex (white arrowhead) has a focal breach. (b) shows a fibrous band connecting collection (asterisk) tip (red arrowheads) to the umbilicus (yellow arrow). (c) The axial view of the diverticulum mimics a well-described pseudo gestational sac appearance of potential Meckel's diverticulum (red arrow). (d) Depicts a normal appendix and the ileocecal junction with their communication with the cecum.

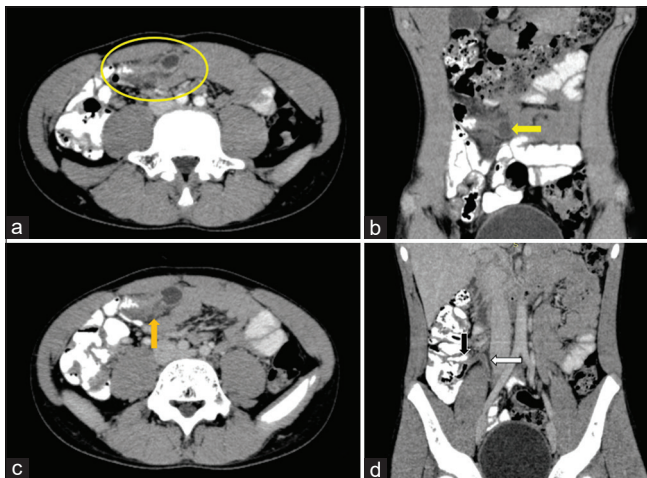


Figure 2: Axial and coronal reformatted images of contrast-enhanced Computed Tomography with positive oral contrast of the abdomen of the same patient show (a) an inflamed Meckel's diverticulum with surrounding fat stranding and collection at its apex (area within yellow oval), (b) the origin of the diverticulum from the antimesenteric aspect of the ileum (yellow arrow), (c) shows a focal breach in its posterior wall (orange arrow), and (d) shows a normal appendix (white arrow) and ileocecal junction (black arrow).

to the umbilicus [Figure 1b]. The axial section through the diverticulum showed a pseudogestational sac-like appearance [Figure 1c], well described in the literature for potential Meckel's diverticulitis.^[1] A normal appendix suggested the possibility of perforated Meckel's diverticulitis [Figure 1d]. A contrast-enhanced computed tomography with positive oral contrast abdomen pelvis was performed,

which confirmed the diagnosis of Meckel's diverticulitis with a localized intraluminal collection at its apex and a focal breach in its posterior wall [Figure 2]. The patient first underwent diagnostic laparoscopy to assess complications and the feasibility of performing laparoscopic removal of the diverticulum, followed by complete surgical excision of the diverticulum and mesodiverticular band [Figure 3]. The surgical specimen was sent for histology which showed ectopic gastric tissue [Figure 4]. The patient had an uneventful course post-surgery and was discharged within 48 h of surgery. No complications were encountered on follow-up in routine surgical outpatient department after 15 days.

DISCUSSION

Embryology

The omphalomesenteric duct is an embryonic structure that connects the primitive midgut with the yolk sac till the 7th intrauterine week; subsequently, it obliterates to form a thin fibrous band which gradually involutes by the 10th intrauterine week. The incomplete regression of the omphalomesenteric duct can result in a range of anomalies [Figure 5], such as (a) umbilicoileal fistula; (b) Meckel's diverticulum; (c) Vitelline sinus; (d) omphalomesenteric duct cyst; and (e) fibrous cord. These account for 98% of all the anomalies of the omphalomesenteric duct.

Anatomy

Meckel's diverticulum, named after Sir Johann Friedrich Meckel, a surgeon who first described incomplete obliteration of the omphalomesenteric duct in 1809. It arises when the ileal end of the omphalomesenteric duct remains patent, and the umbilical end is atrophied. It is a true diverticulum comprising all the layers of the intestinal wall. It arises from the antimesenteric border of the ileum. However, cases of mesenteric origin of Meckel's diverticulum have been reported.^[2,3] It is supplied by a persistent vitelline artery which arises from the distal ileal branch of the superior mesenteric artery.^[4,5] The length of the Meckel's diverticulum ranges from 1 to 10 cm in most reported cases, with a mean length of 5 cm, as in our case. Giant Meckel diverticulum (≥ 5 cm) is rare and often associated with intestinal obstruction complications.^[6]

Complications

Intestinal obstruction is the most common complication in adult patients.^[7] The second most common complication in adults is diverticulitis and perforation (as in our case), occurring at a combined rate of almost 20% and are often indistinguishable from acute appendicitis until visualization in

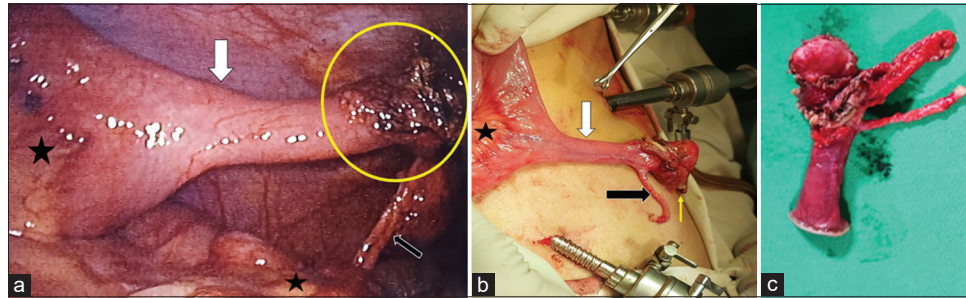


Figure 3: (a) Diagnostic laparoscopy and (b) intraoperative images of the same patient show a diverticulum arising from the antimesenteric border of the ileum (white arrows) with an inflamed ulcerated tip (area within the circle) and a focal site of perforation near its tip (yellow arrow). This image also shows the mesentery of the ileum (black asterisks) and mesodiverticular band (black arrow). (c) Image of the resected diverticulum.

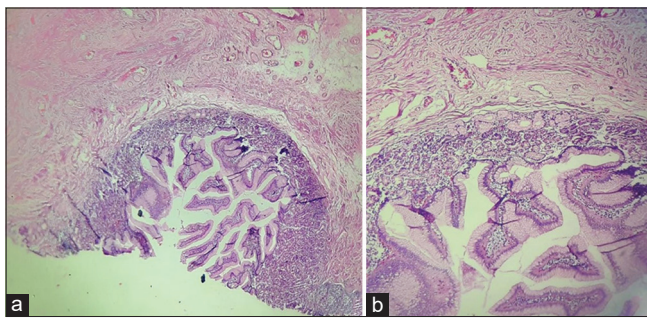


Figure 4: Histopathological slides (a and b) of the resected specimen show heterotopic gastric mucosa.

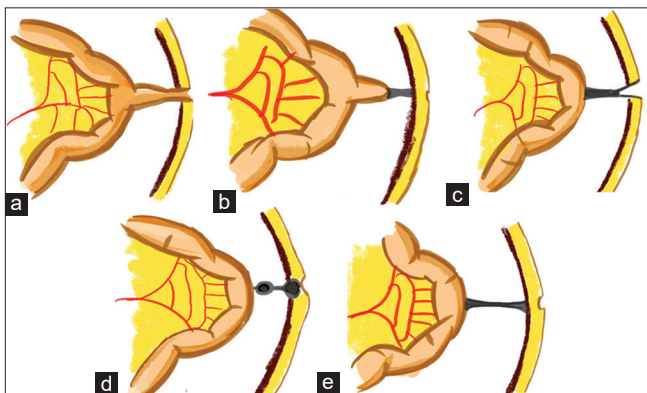


Figure 5: Diagrammatic representation of various anomalies due to incomplete regression of embryonic omphalomesenteric duct are depicted: (a) Umbilico-ileal fistula, (b) Meckel's diverticulum with a fibrous band, (c) Vitelline sinus, (d) Vitelline cyst, and (e) Fibrous cord.

the operating room.^[8] Moore and Johnston^[9] reported that in a series of 50 patients, 40% of patients with Meckel's diverticulum had a pre-operative diagnosis of acute appendicitis.

Hemorrhage is the most common presentation in children, reported in over 50% of cases.^[10] About 90% of the bleeding diverticula contain heterotopic gastric mucosa, as in our case. This mucosa allows the diverticulum to be picked up

radiologically by the ^{99m}Tc-pertechnetate Meckel's scan. The other less common forms of heterotopic tissue described are pancreatic, carcinoid, duodenal, colonic, and endometrial.

In cases of active bleeding, to see contrast blush on CT angiography, bleeding should occur at a minimum rate of >0.5 mL/min.^[5] In patients presenting with occult lower gastrointestinal bleeding with negative scintigraphy, angiography can aid in the diagnosis of Meckel's diverticulum by demonstrating the presence of a persistent vitelline artery.

A comprehensive review conducted by the Mayo Clinic on 1476 patients suggested the following risk factors associated with symptomatic diverticula – (1) patient younger than 50 years; (2) male gender; (3) diverticulum length >2 cm; and (4) ectopic or abnormal features within a diverticulum. Their study showed that even with the fulfillment of a single criterion, the overall proportion of symptomatic Meckel diverticulum was 17%. Hence, it recommended the removal of all incidental diverticula that fulfill any of these four criteria.^[11]

CONCLUSION

Due to the poor availability of cross-sectional studies, there is considerable dependence on ultrasonography in two or three-tier cities. Knowing ultrasonogram features of Meckel's diverticulitis would re-enforce the trainees to recollect that all blind ending bowel loops in the right iliac fossa need not necessarily be the appendix. Hence an attempt for proper documentation of the origin of any blind ending bowel loop is desirable.

TEACHING POINTS

- Blind ending bowel loop in the right iliac fossa is not always appendix; the possibility of Meckel's diverticulum should be raised when the exact origin from the cecum is not demonstrated.
- All fluid-filled structures with gut signature in umbilical or periumbilical location on ultrasonogram

should be evaluated for the possibility of congenital remnants such as omphalomesenteric cyst, complicated Meckel's diverticulum, and intestinal duplication cyst.

- Imaging helps in the early diagnosis of Meckel's diverticulitis and prevents life-threatening complications such as small bowel obstruction, gangrenous diverticulum, perforative peritonitis, and bleeding.
- Raising the possibility of Meckel's diverticulitis on imaging saves complications associated with emergency surgical exploration, and a diagnostic laparoscopy or nuclear scans can be performed.

MCQs

1. All are true about Meckel's diverticulum except?
 - a. Arises from the mesenteric border
 - b. 2 inches from the ileocecal junction
 - c. 2 cm in length
 - d. Has a gut signature

Answer Key: a

2. Which of the following condition is a predisposing condition for Meckel's diverticulitis?
 - a. Typhoid
 - b. Crohn's disease
 - c. VACTERAL
 - d. Intestinal Koch's

Answer Key: b

3. Which of the following is not a complication of Meckel's diverticulum?
 - a. Intestinal obstruction
 - b. Gastrointestinal hemorrhage
 - c. Hernia
 - d. Hematuria

Answer Key: d

Ethical approval

Institutional Review Board approval is not required/waived-off.

Declaration of patient consent

Patient's consent not required as patient's identity is not disclosed or compromised.

Financial support and sponsorship

Nil.

Conflicts of interest

There are no conflicts of interest.

Use of artificial intelligence (AI)-assisted technology for manuscript preparation

The authors confirm that there was no use of artificial intelligence (AI)-assisted technology for assisting in the writing or editing of the manuscript and no images were manipulated using AI.

REFERENCES

1. El-Maadawy SM, Alaaeldin N, Zefov VN. Value of sonographic pseudogestational sac sign in the diagnosis of Meckel diverticulum in children presenting with bleeding per rectum: A 15-year prospective study. *Egypt J Radiol Nucl Med* 2021;52:195.
2. Abbas SH, Akbari K, Mason J, Booth M. Mesenteric Meckel's diverticulum: An unusual cause of small bowel intussusception. *BMJ Case Rep* 2016;2016:bcr2016214830.
3. Singh A, Panda SS, Sharma N, Bajpai M. Meckel's diverticulum at uncommon mesenteric location. *J Indian Assoc Pediatr Surg* 2013;18:127-8.
4. Mitchell AW, Spencer J, Allison DJ, Jackson JE. Meckel's diverticulum: Angiographic findings in 16 patients. *AJR Am J Roentgenol* 1998;170:1329-33.
5. Levy AD, Hobbs CM. From the archives of the AFIP. Meckel diverticulum: radiologic features with pathologic Correlation. *Radiographics* 2004;24:565-87.
6. Akbulut S, Yagmur Y. Giant Meckel's diverticulum: An exceptional cause of intestinal obstruction. *World J Gastrointest Surg* 2014;6:47-50.
7. Leijonmarck CE, Bonman-Sandelin K, Frisell J, Räf L. Meckel's diverticulum in the adult. *Br J Surg* 1986;73:146-9.
8. Ymaguchi M, Takeuchi S, Awazu S. Meckel's diverticulum. Investigation of 600 patients in Japanese literature. *Am J Surg* 1978;136:247-9.
9. Moore T, Johnston AO. Complications of Meckel's diverticulum. *Br J Surg* 1976;63:453-4.
10. Rutherford RB, Akers DR. Meckel's diverticulum: A review of 148 pediatric patients, with special reference to the pattern of bleeding and to mesodiverticular vascular bands. *Surgery* 1966;59:618-26.
11. Park JJ, Wolff BG, Tollefson MK, Walsh EE, Larson DR. Meckel diverticulum: The Mayo Clinic experience with 1476 patients (1950-2002). *Ann Surg* 2005;241:529-33.

How to cite this article: Tekriwal K, Bhoir AA, Karthik HS. Meckel's diverticulitis: A frequently overlooked mimic of appendicitis. *Case Rep Clin Radiol.* 2024;2:103-6. doi: 10.25259/CRCR_43_2023